

The Application of Forensic Principles for the
Analysis of
the Autopsy Skull X-Rays of President
Kennedy
and
a Review of the Brain Photographs

Michael Z. Chesser, M.D.
November 16, 2017

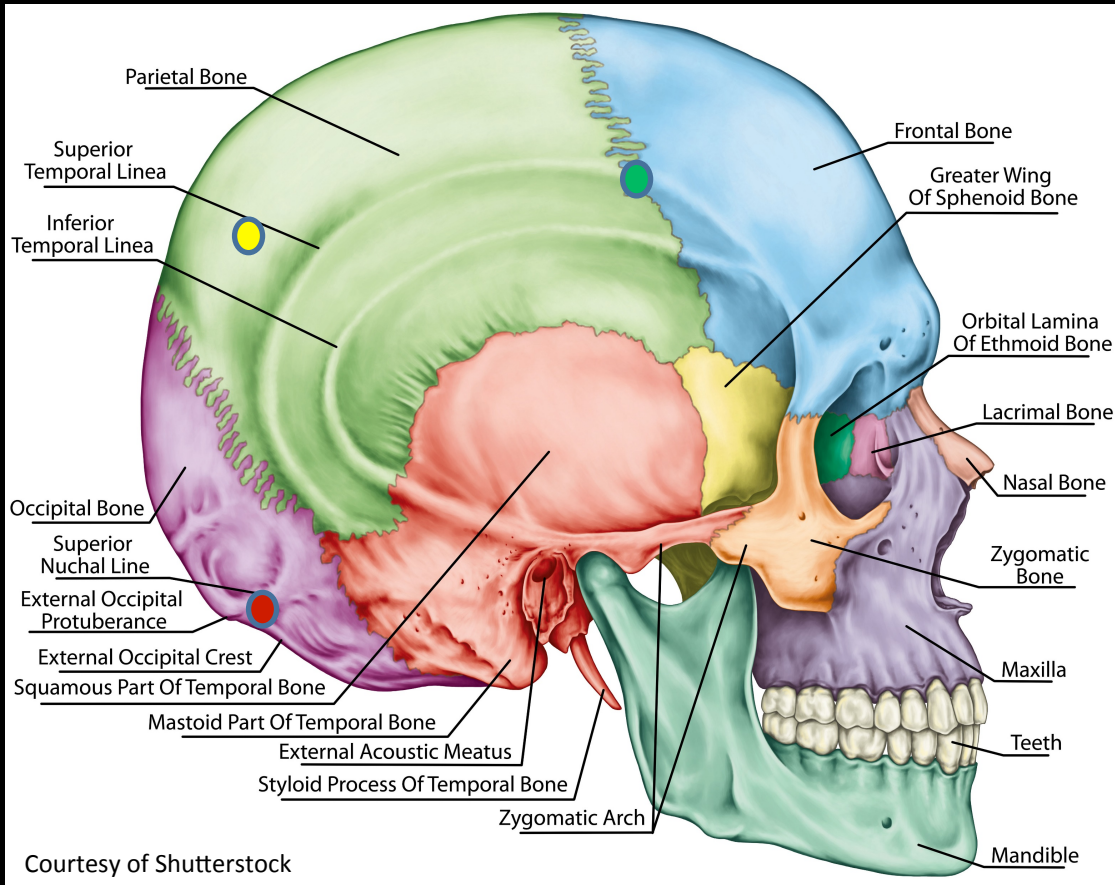
Introduction

- The autopsy x-rays do not support the conclusions of the Warren Commission or of the House Select Committee on Assassinations, that a bullet fired from the TSBD 6th floor caused the head wound(s)
- The x-rays show evidence of a right frontal entry wound and of a right lower occipital entry
- There is evidence of alteration of the autopsy skull x-rays and of some of the autopsy photographs

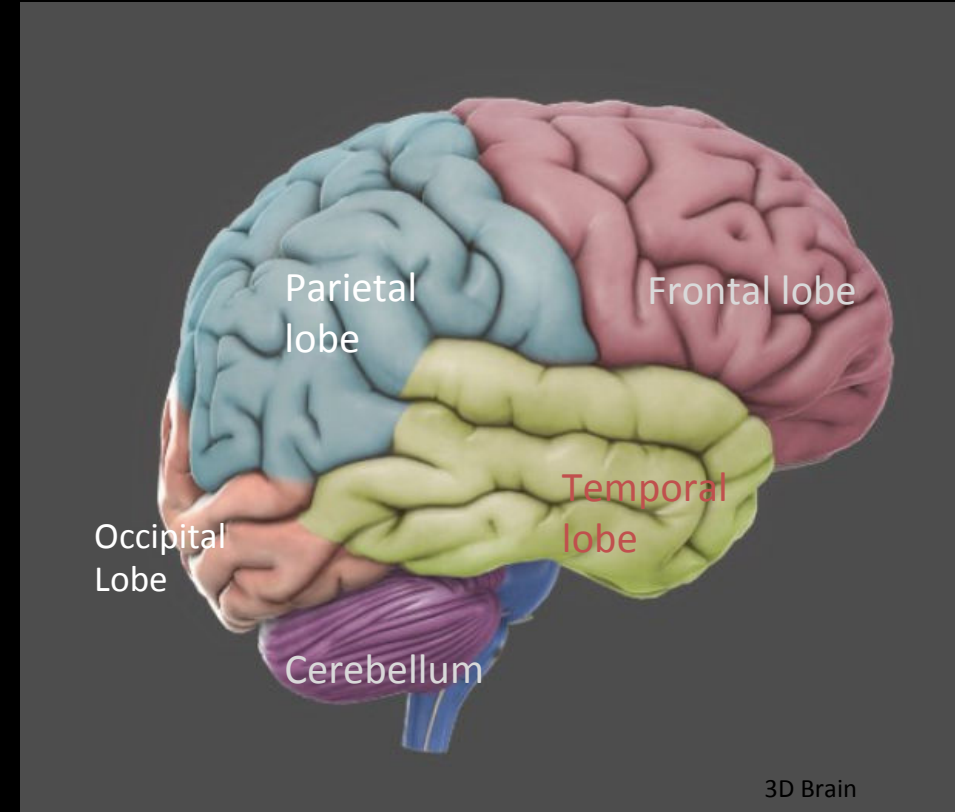
Deed of Gift

- **1965** – Justice Department (Katzenbach) drafted HR9545, which was approved by Congress and became public bill 89-318, requiring transfer of autopsy materials to the National Archives
- **RFK vigorously protested**
- The **Deed of Gift** of the autopsy materials was established (10/29/66)
- Burke Marshall / **Paul Kirk** – attorneys representing the Kennedy family for the Deed of Gift.

Skull and Brain Anatomy

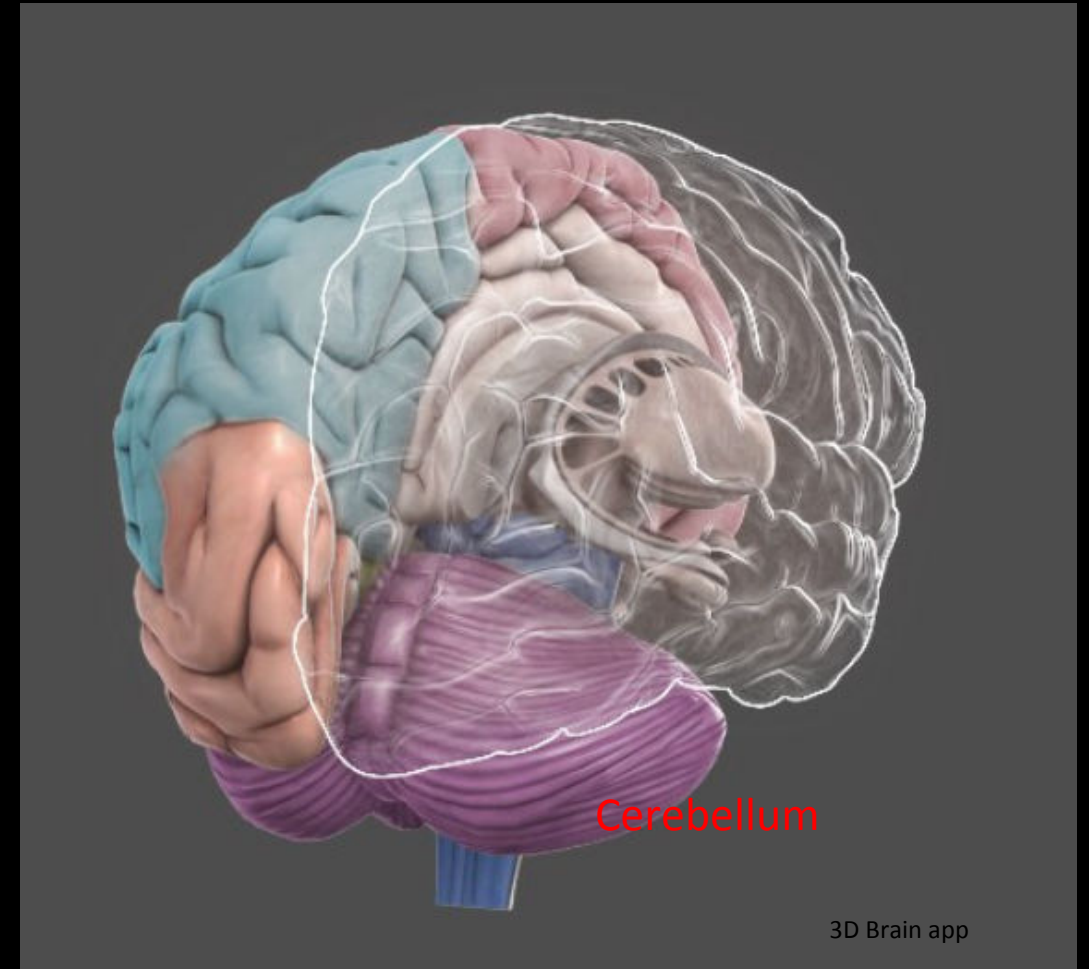
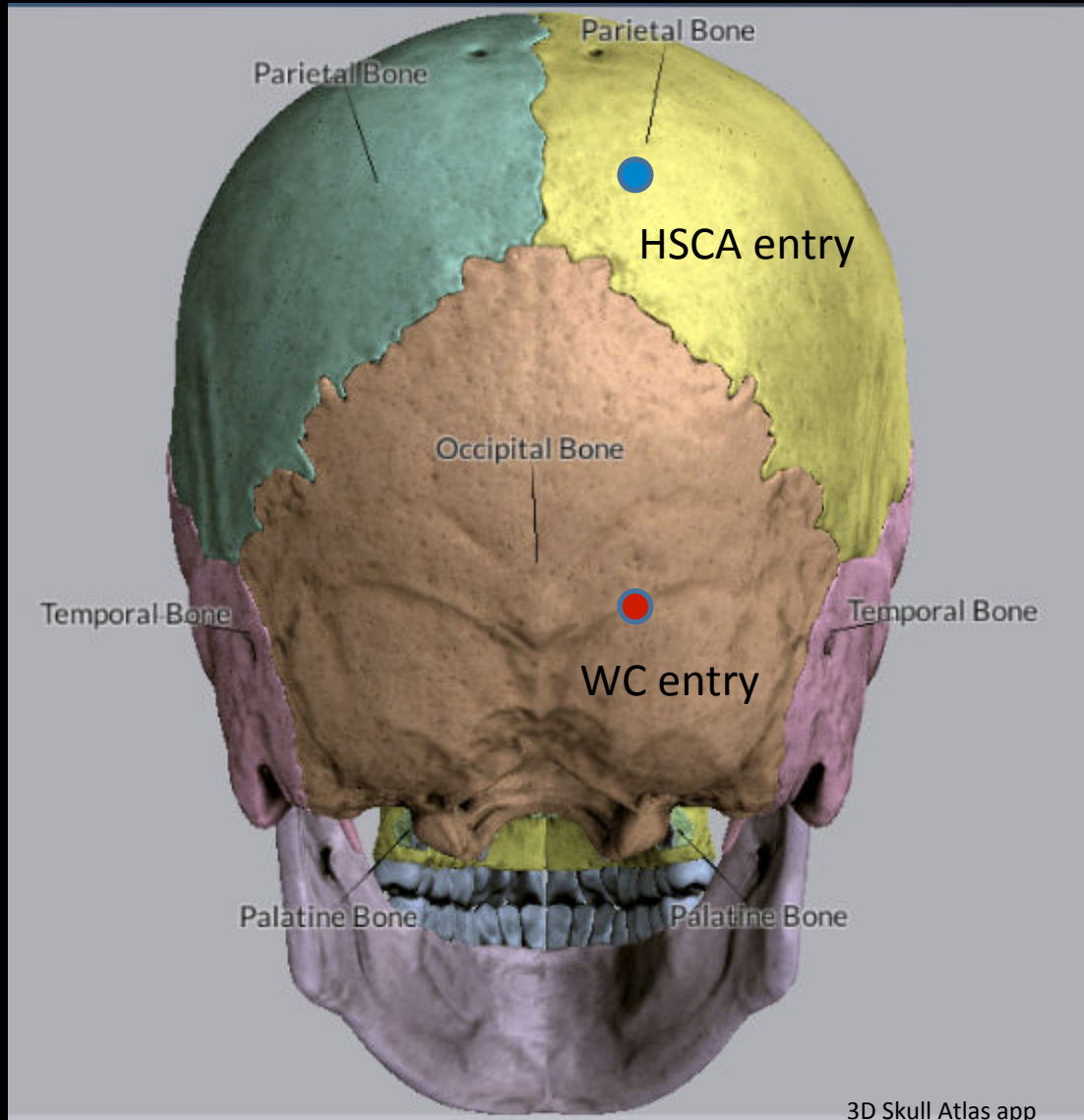


- Warren Commission entry site
- HSCA entry site
- HSCA exit site



The Warren Commission concluded that a bullet fired by Lee Harvey Oswald, from the TSBD 6th floor, entered the skull in the right lower occipital area ●, exiting somewhere over the right frontoparietal region. The HSCA raised the entry site ● 10 cm, and designated ● (stephanion) as the exit site.

Posterior (back of head) view of the WC and HSCA entry sites and of the cerebellum



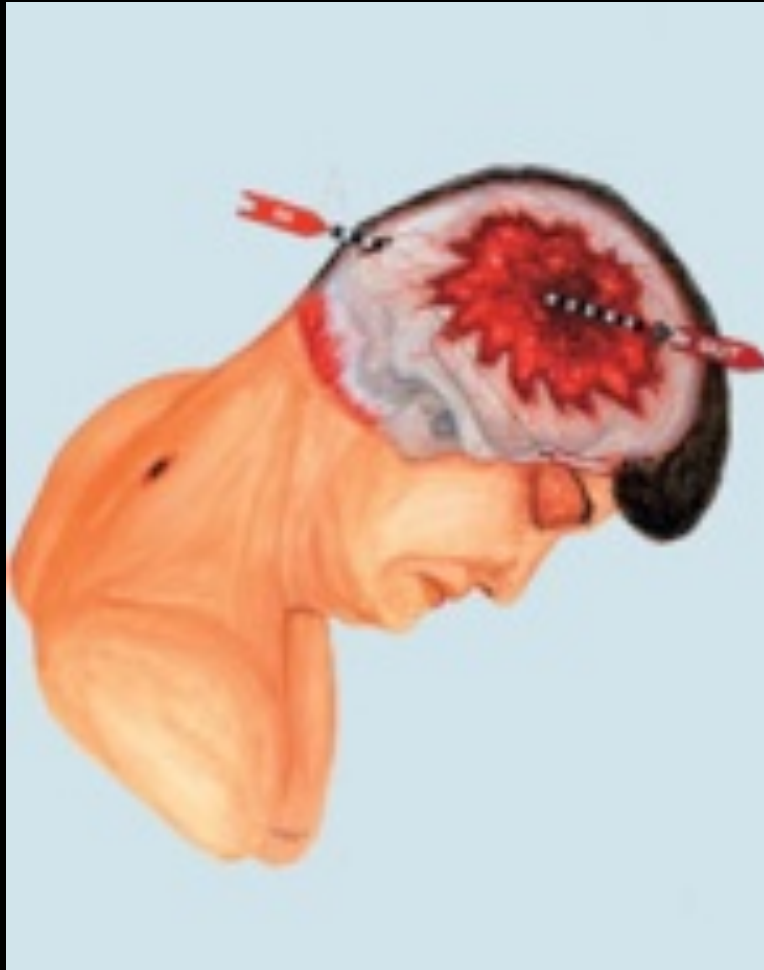

Zapruder frame 312

Notice the head position, tilted forward and to the left, 1 frame before the massive head wound

Warren Commission

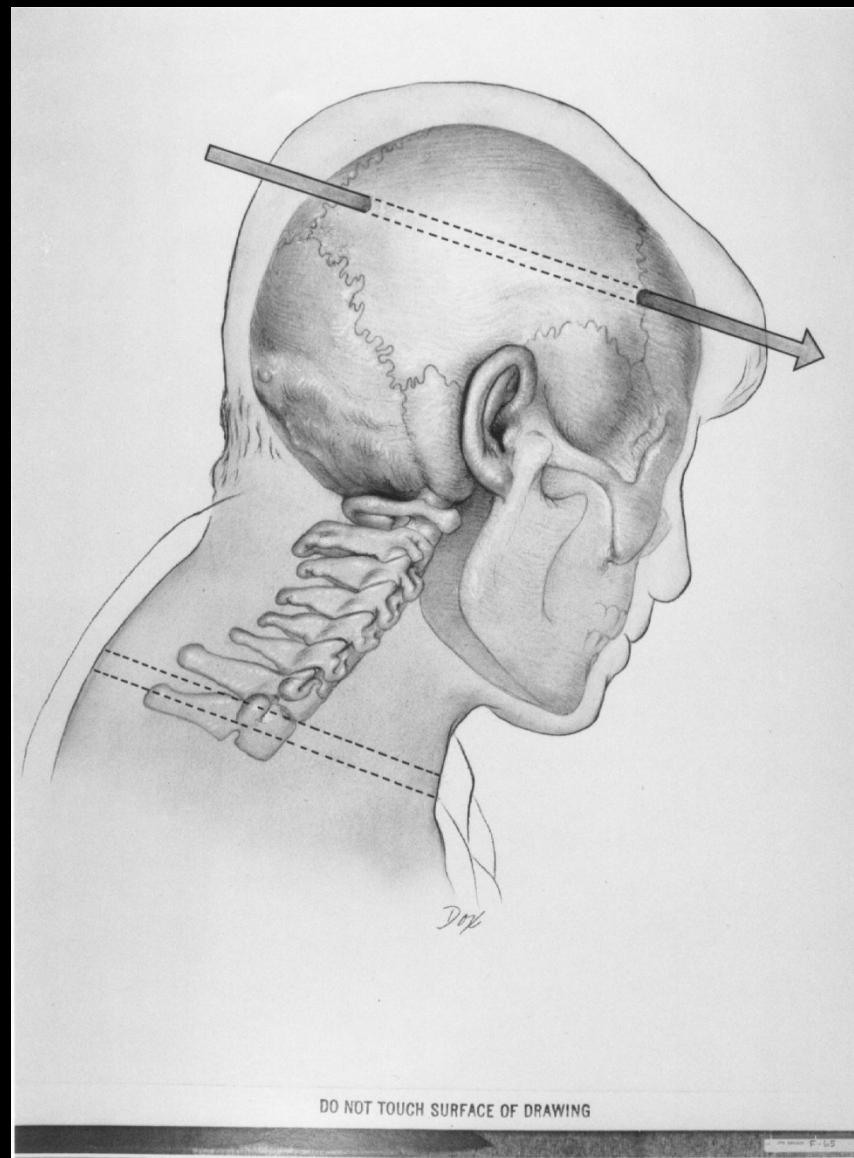
This illustration for the Warren Commission Report exaggerated the forward flexion of the President's neck



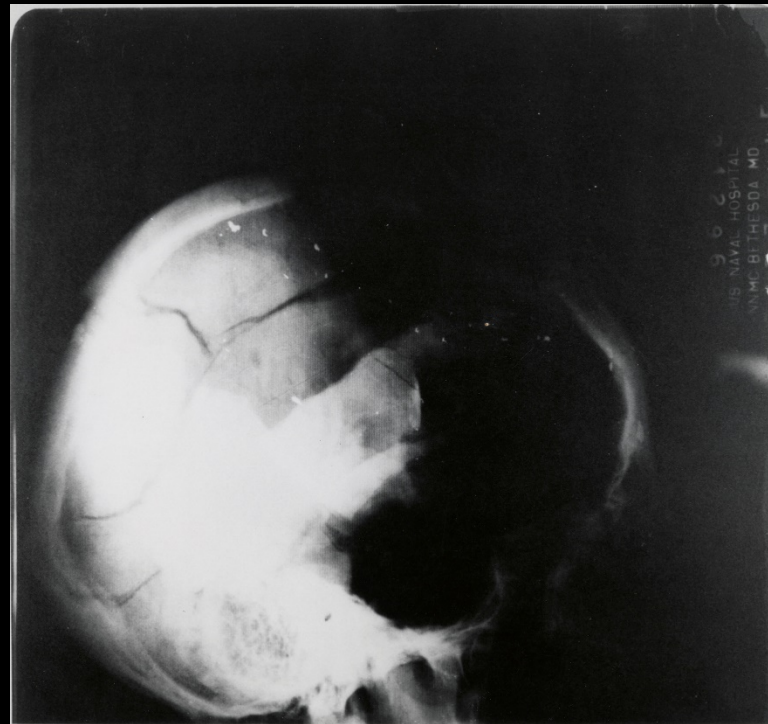
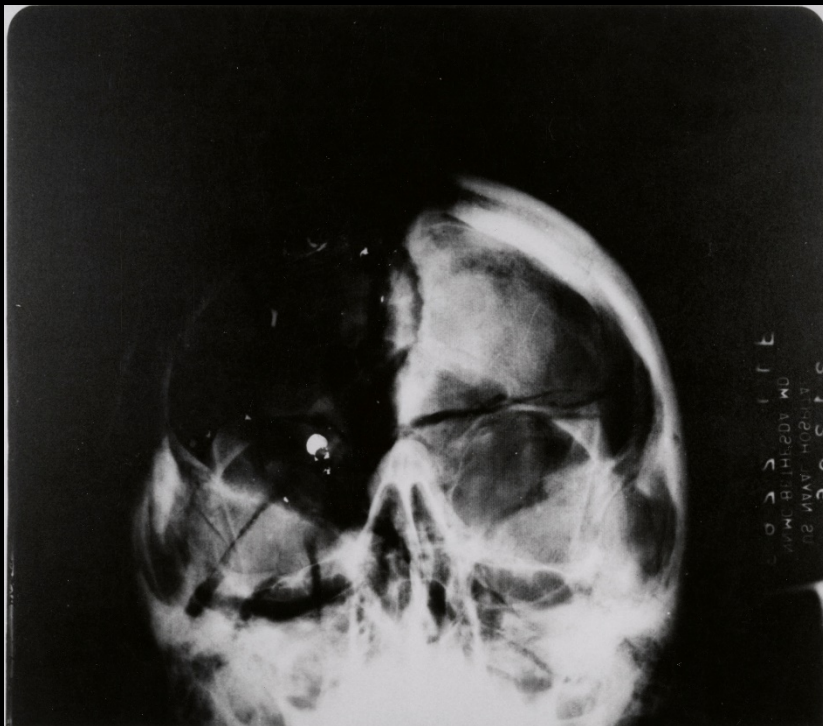
Rydberg illustration of bullet path

Clark Panel 1968 and House Select Committee on Assassinations (HSCA) Medical Panel 1978 - entry site moved up ~ 10 cm

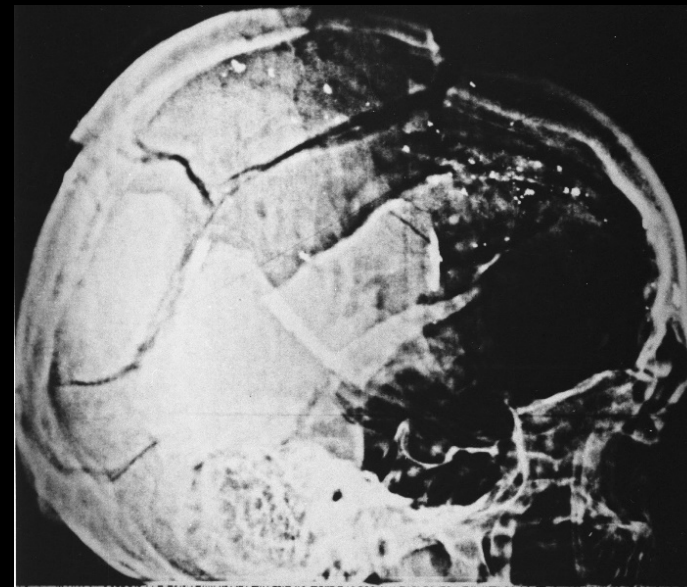
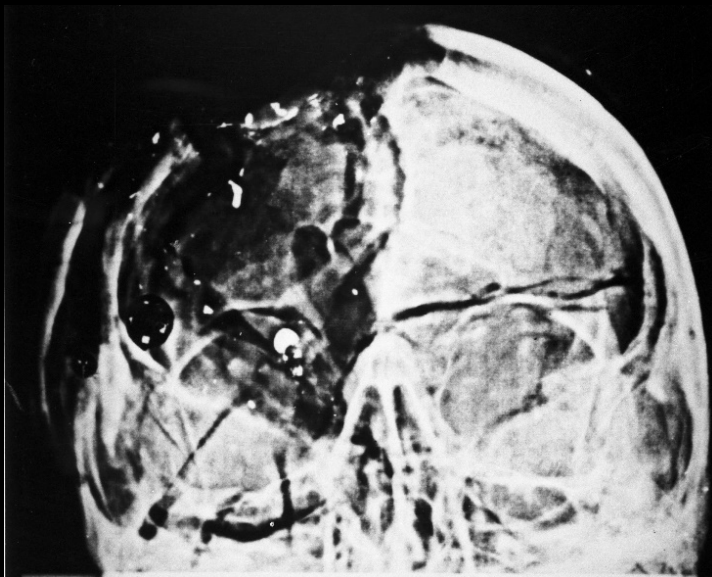
The autopsy pathologists described an entry wound on the right lower occipital skull, adjacent to the external occipital protuberance. They argued when the HSCA panel moved the entry site up 10 cm. **Why did the HSCA medical panel overrule the pathologists?**



“Original”
autopsy x-ray
images from
HSCA Report
(obtained
from
National
Archives)

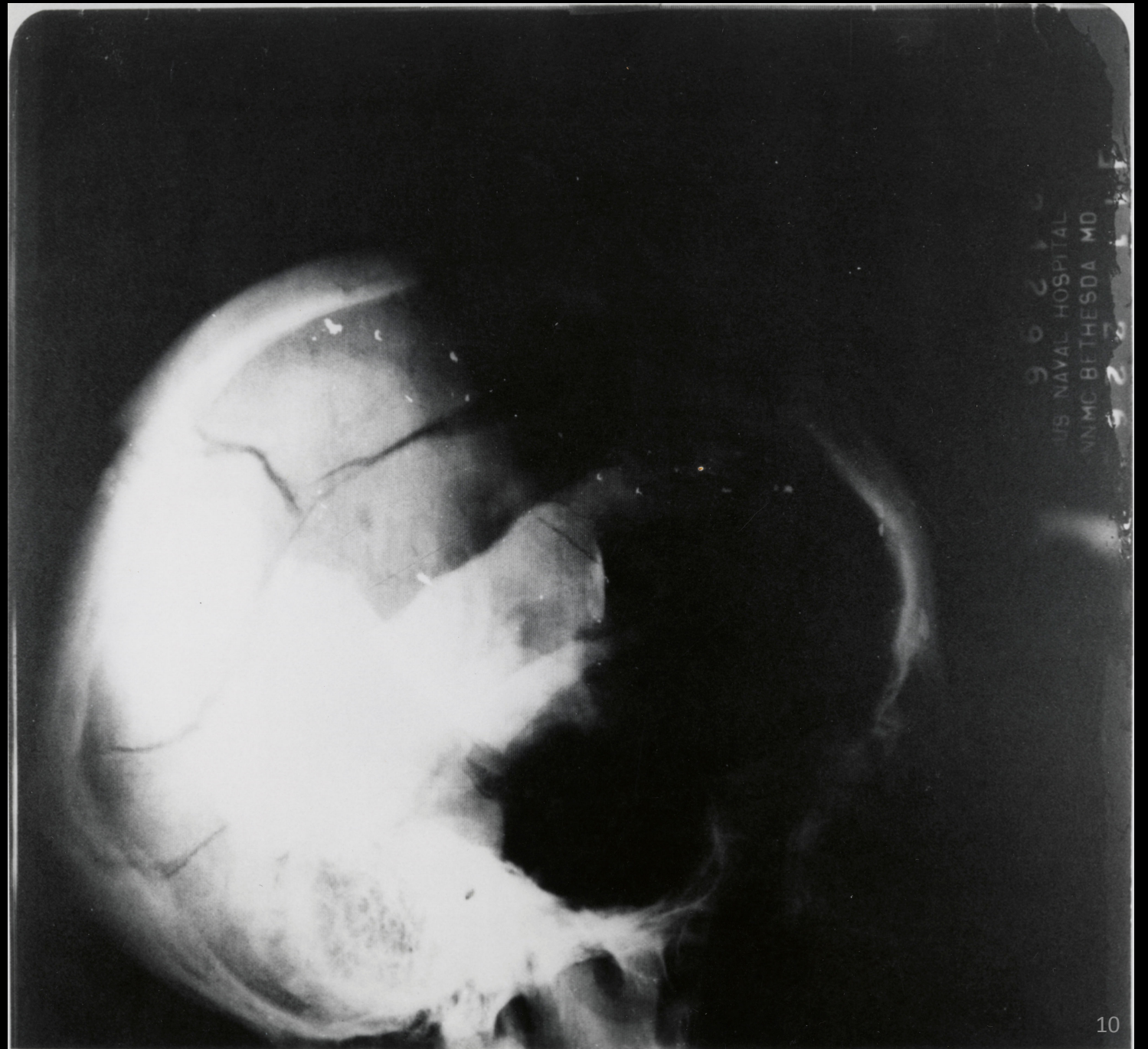


HSCA
computer
enhanced
X-ray images
from HSCA
report (from
National
Archives)



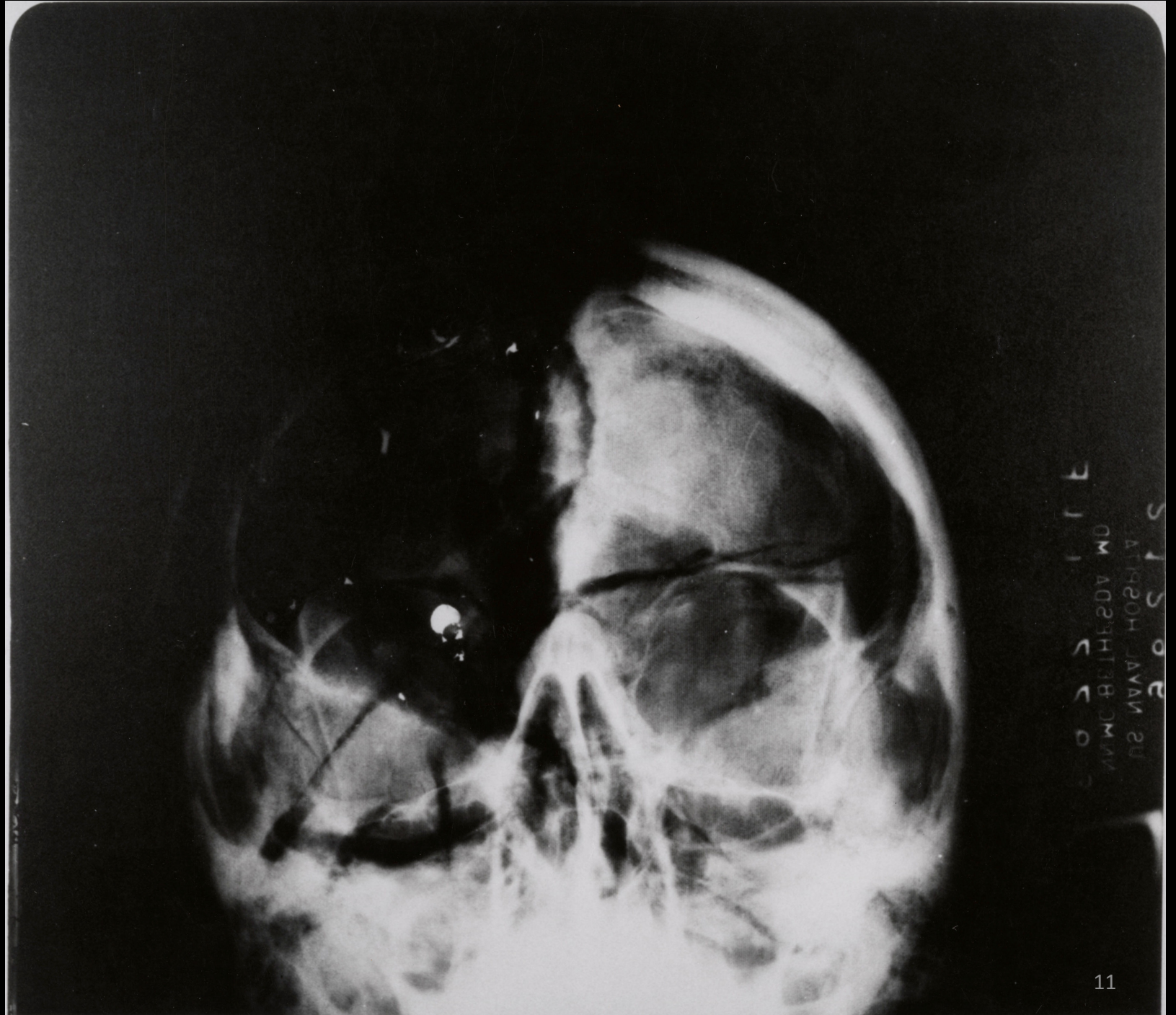
Original Right Lateral

Compared to the actual film at the Archives, this image from the HSCA report appears blurred, and the whiteness of the back of the head and darkness of the front are exaggerated.



Original AP

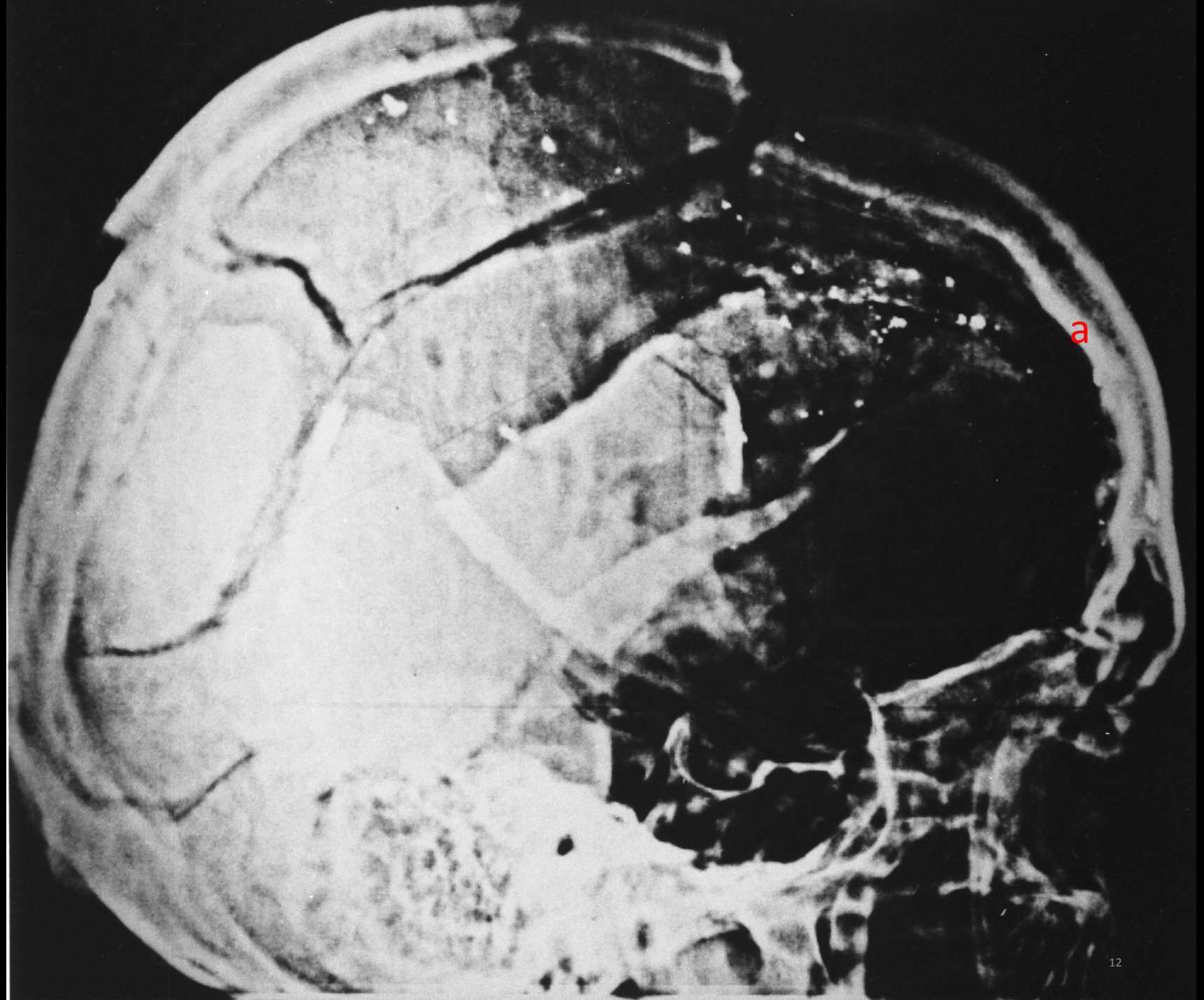
The bright object measures 6.5 mm in diameter, and there is no counterpart found on the lateral image. There was no discussion of this in the Warren Commission report, and no official x-ray interpretation was included in the report. No bullet fragment of this size was removed at the time of the autopsy. Within the outline of this bright object are the shapes of two fragments. I agree with Dr. David Mantik that the film was copied, and this bright object was added to the image.



HSCA computer enhanced right lateral

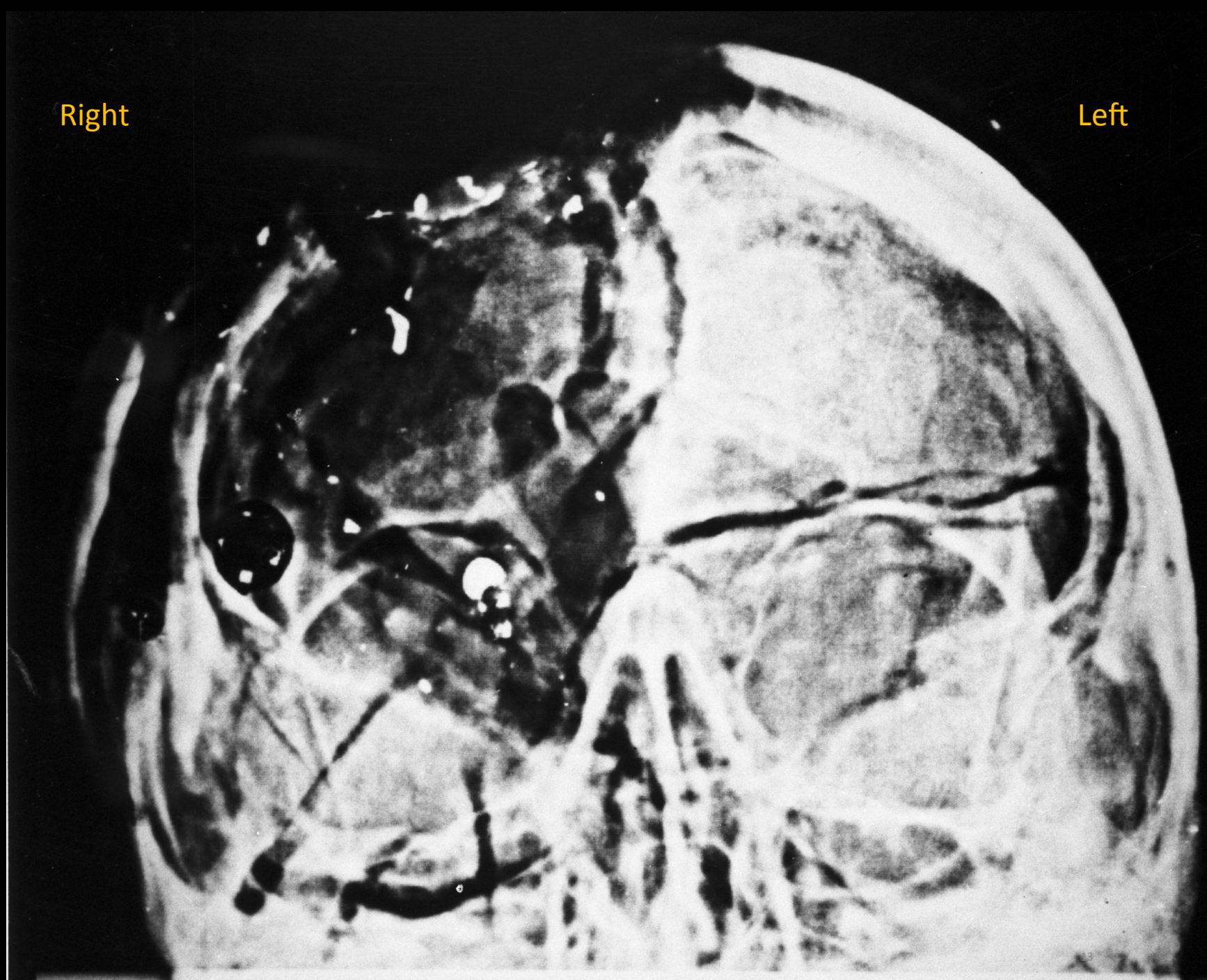
The HSCA had the cranial x-rays enhanced by computer methods at Aerospace Corporation, under the direction of former Army radiologist Dr. G.M. McDonnell.

The right side of the frontal bone had detached and fallen backward, slightly into the cranial vault (a)



HSCA AP x-ray

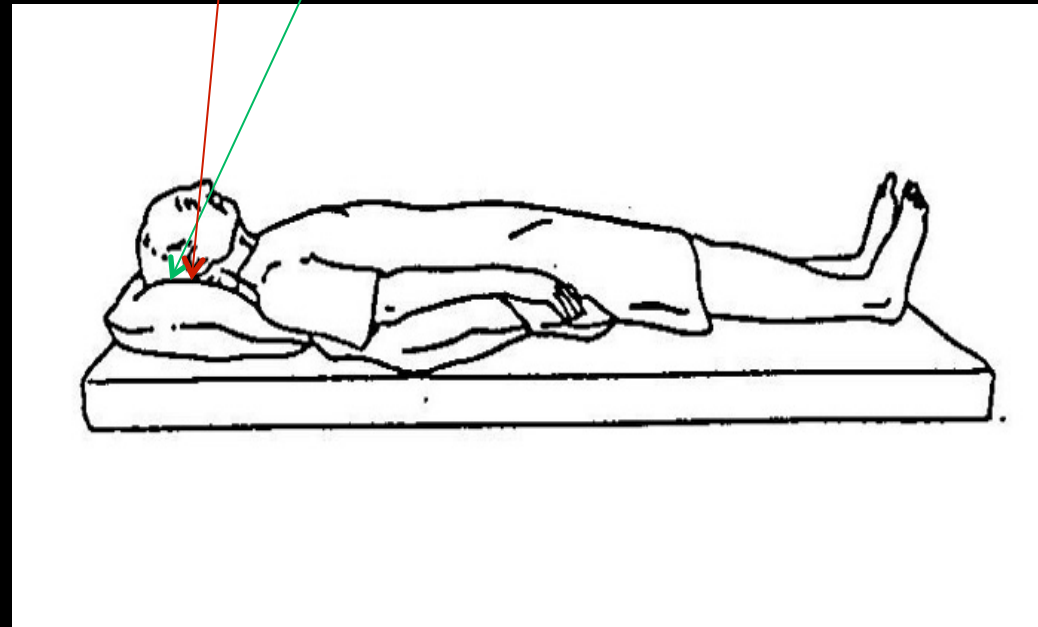
The AP image shows the massive amount of injury to the right side of the skull, with loss of bone extending across the midline to the left side.



Angle of AP X-Ray

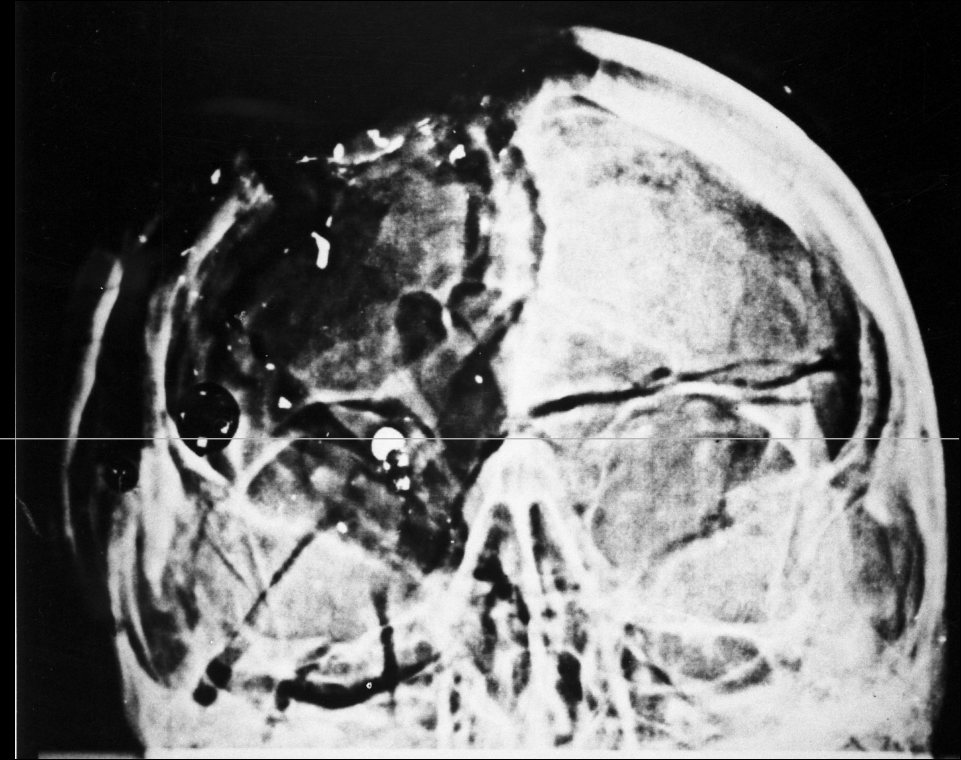
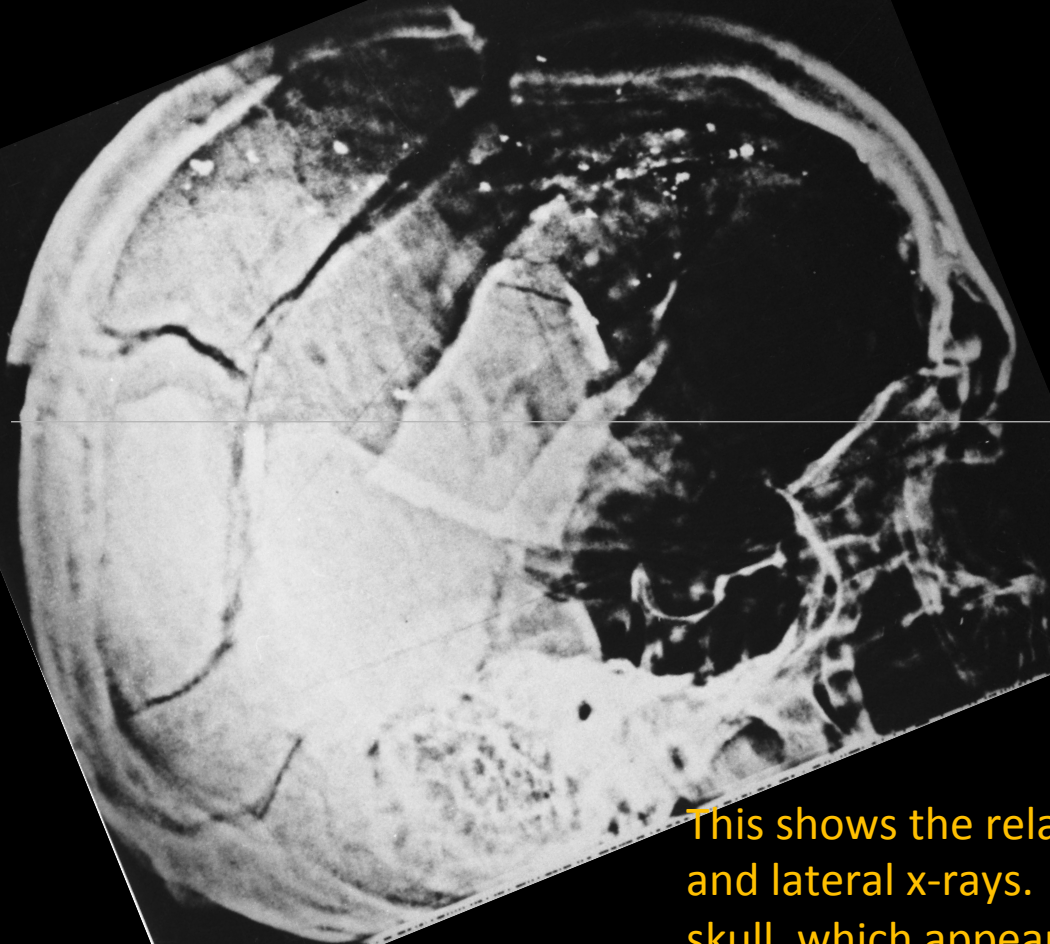
Standard
angle

Actual angle of AP
autopsy image



The standard angle of the x-ray beam for an AP skull x-ray is shown in red, and the approximate angle of the autopsy AP skull x-ray is shown on the right, in green. The actual angle used for the x-ray was found to be ~ 15 degrees above a line from the inferior orbital rim to the petrous apex.

HSCA computer enhanced images



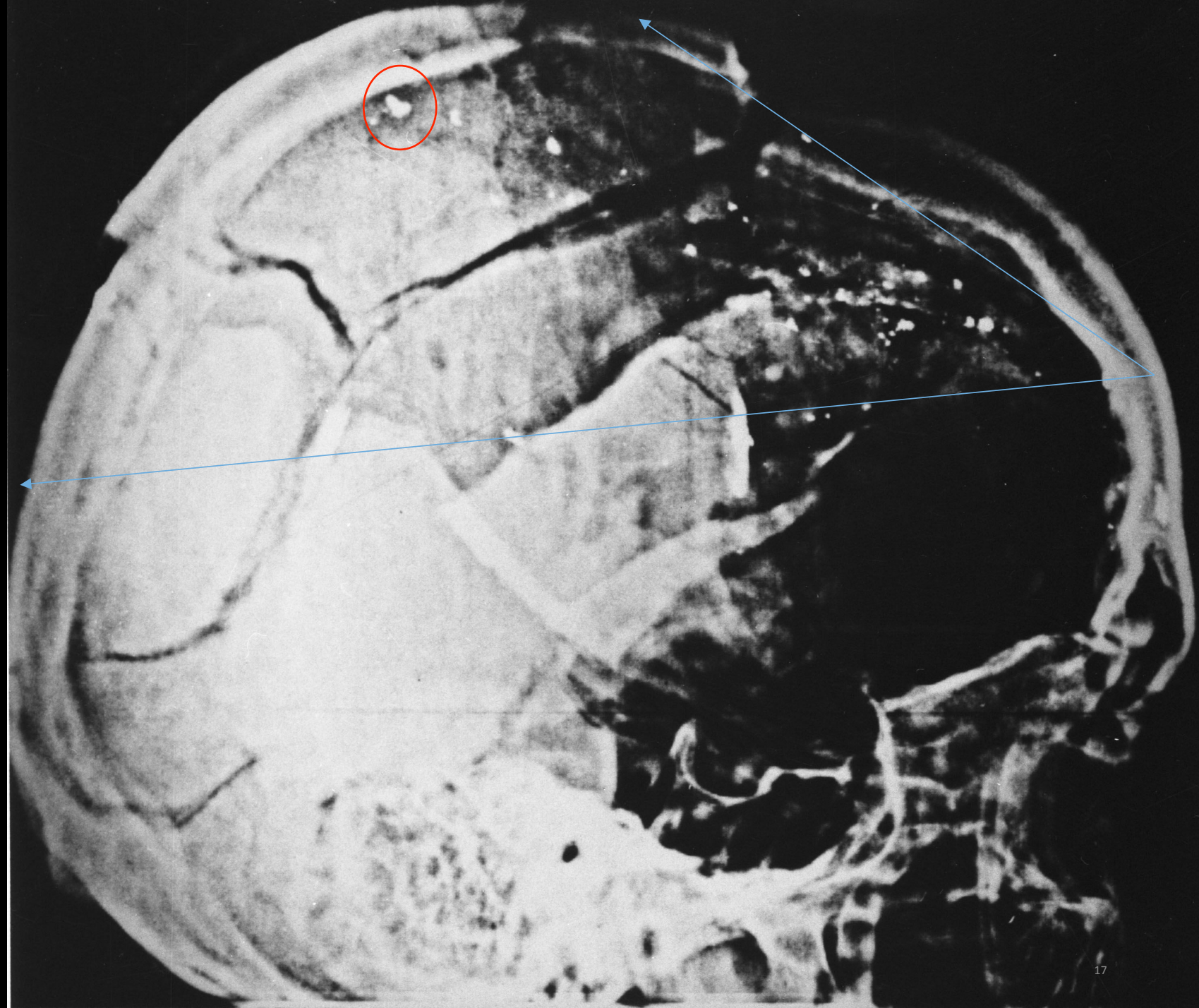
This shows the relationship between corresponding points on the vertical axis of the AP and lateral x-rays. The 6.5 mm bright object overlaps a small fragment at the back of the skull, which appears to lie within the scalp. This fragment can actually be seen within the diameter of the 6.5 mm object on the "original" x-ray, but not on the computer enhanced image.

Forensic Principles

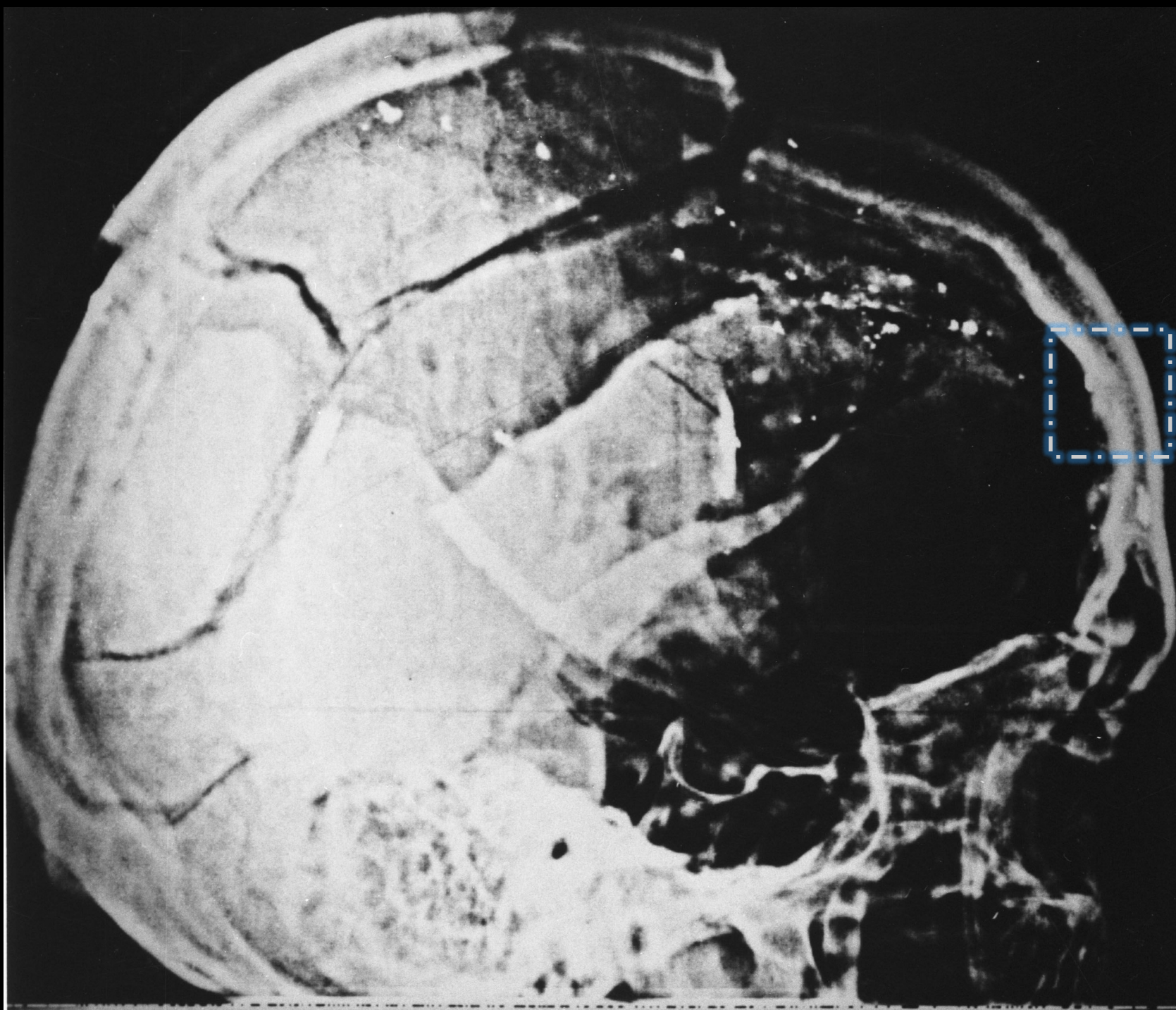
- When a bullet impacts the skull and disintegrates, larger fragments tend to travel further than smaller fragments, because of their kinetic energy.
 - Kinetic energy = $\frac{1}{2} MV^2$
 - M = Mass
 - V = Velocity

Fragment Trail

The fragment trail appears to widen from front to back, and this points toward a frontal entry. The largest fragment seen on the lateral x-ray is circled. The smallest fragments were seen adjacent to the frontal bone, to be discussed.

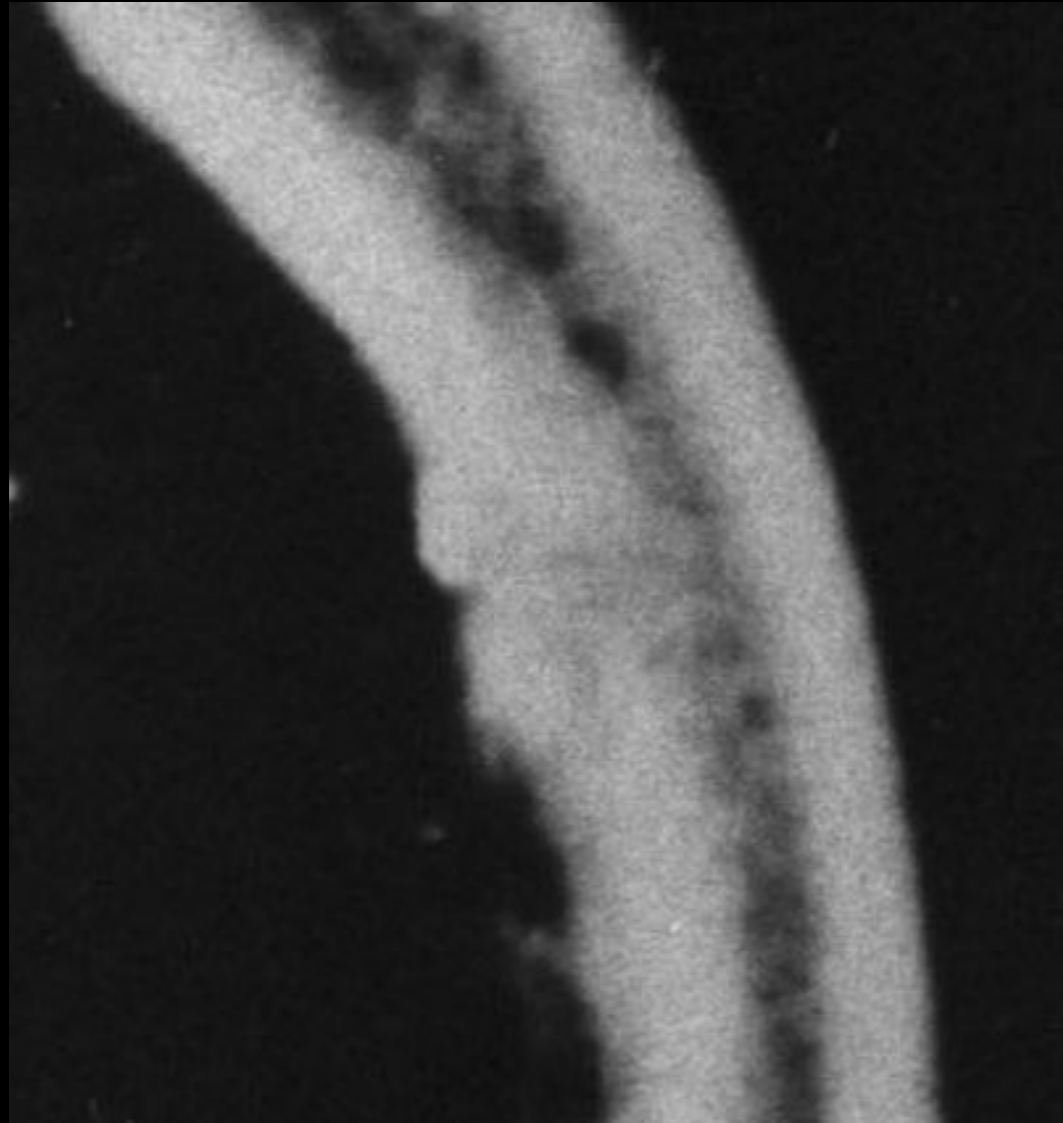


HSCA
Computer
Enhanced
Image
from the
HSCA
Report

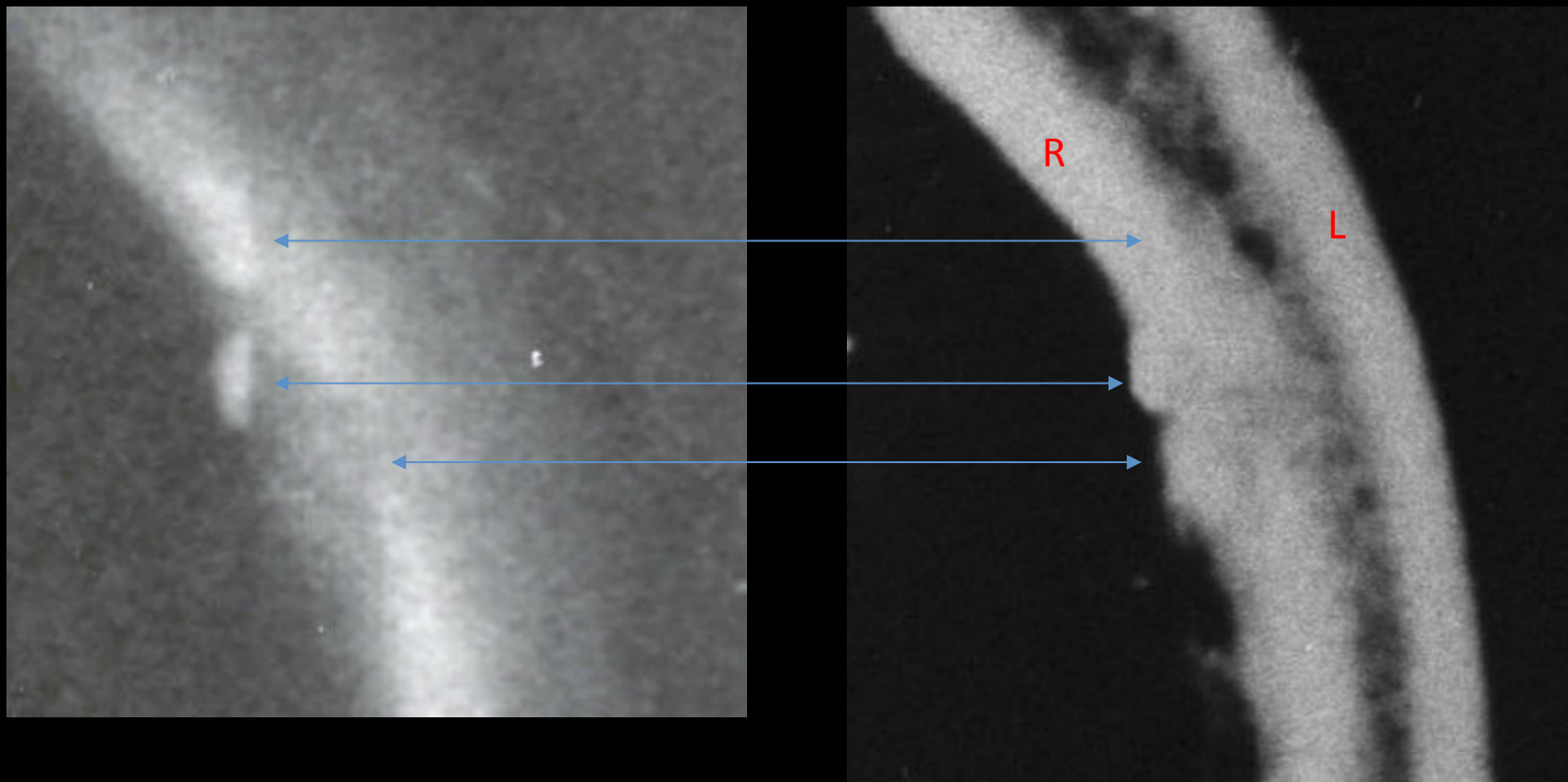


The area within the box has a very unusual appearance, with two white knobby appearing objects on the inner side of the frontal bone.

Close-up of
frontal skull
seen on the
lateral x-ray
image placed in
the HSCA report



Right Frontal Entry Zone Original vs HSCA Image (from the HSCA Report)




To illustrate how the image was altered, lines are drawn between corresponding points on the original and HSCA computer enhanced images from the HSCA report. The gap in the frontal bone on the left has been filled in on the right.

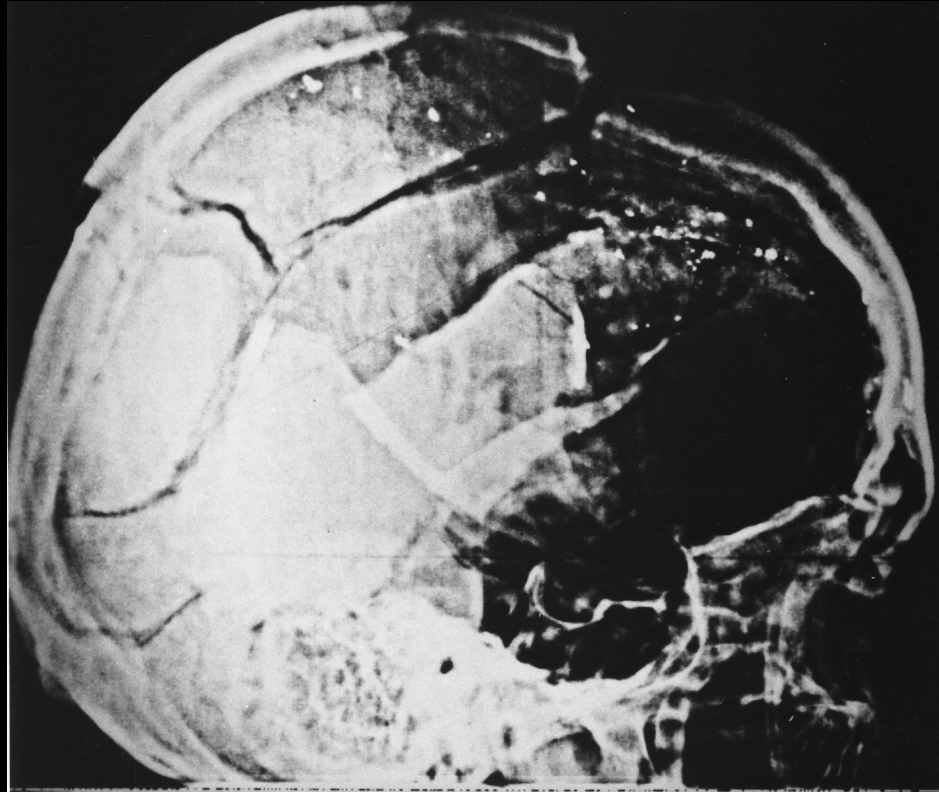
Simulation of the original right lateral skull x-ray viewed at the National Archives II

Fragment trail
of tiny
fragments
noted on the
original right
and left lateral
skull x-rays at
the Archives.

Multiple tiny
fragments also
visible within
and adjacent
to the bony
gap.



Right Frontal Entry Location



The fragment trail supports a right frontal entry site at approximately this location ●
An entry wound at this location would have been covered by hair, and easily missed by the Parkland personnel who focused on resuscitation and the profusely bleeding right occipital wound.

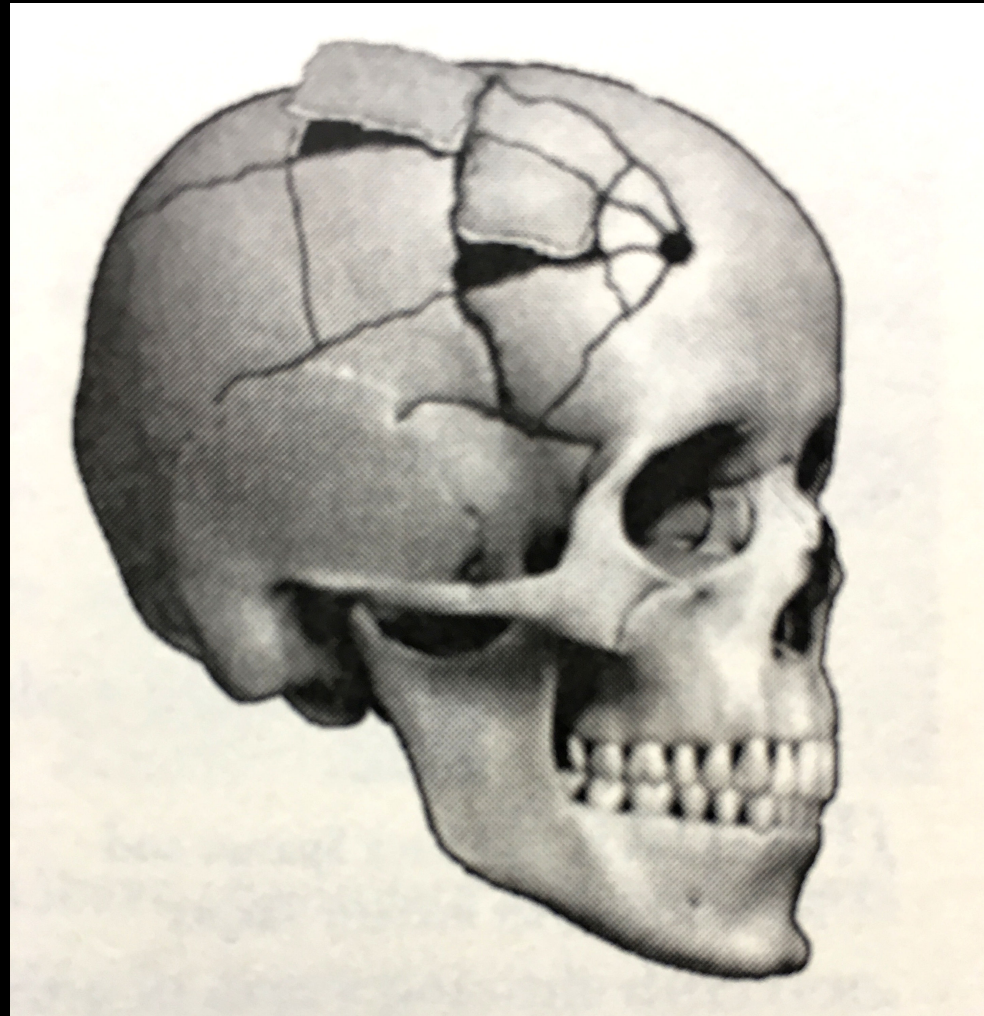
Forensic Principles

- **Two primary types of fractures**
 - **Radial fractures:** radial fractures from entry site are much longer than radial fractures from exit site
 - **Concentric fractures:** concentric fractures near entry site much more prominent than those near exit site
- **Puppe's rule**
 - **Georg Puppe**, German physician, 1903
 - A propagating fracture will not cross a pre-existing fracture

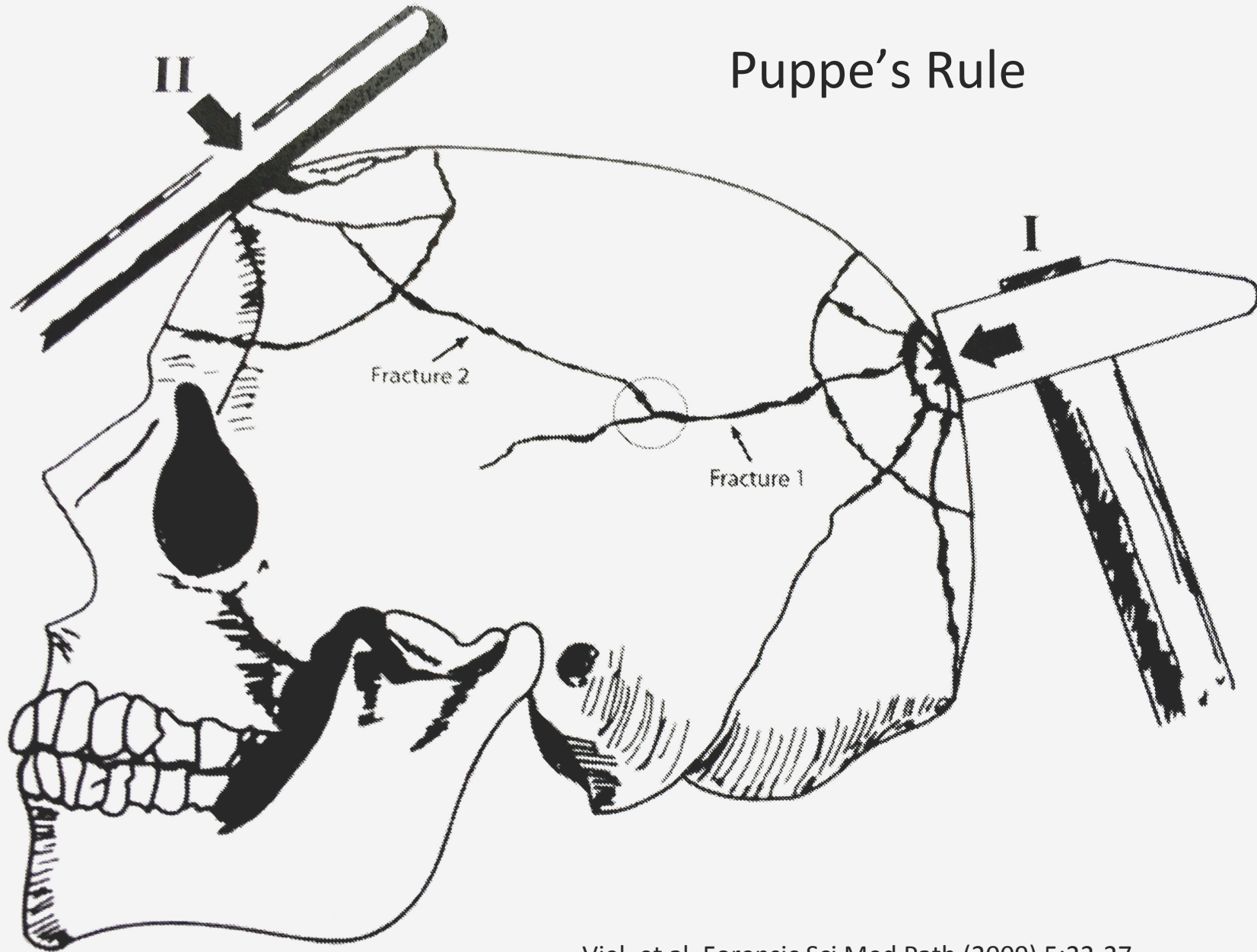
Radial and Concentric Fractures

Radial fractures are like the spokes of a tire, and they travel across the skull faster than the missile which produced them.

Concentric fractures, also known as heaving fractures, are produced by the spreading wave of extreme pressure traveling through the cranial cavity, known as a cavitation cavity. These fractures are shorter, and arc like, and do not cross the radial fractures.



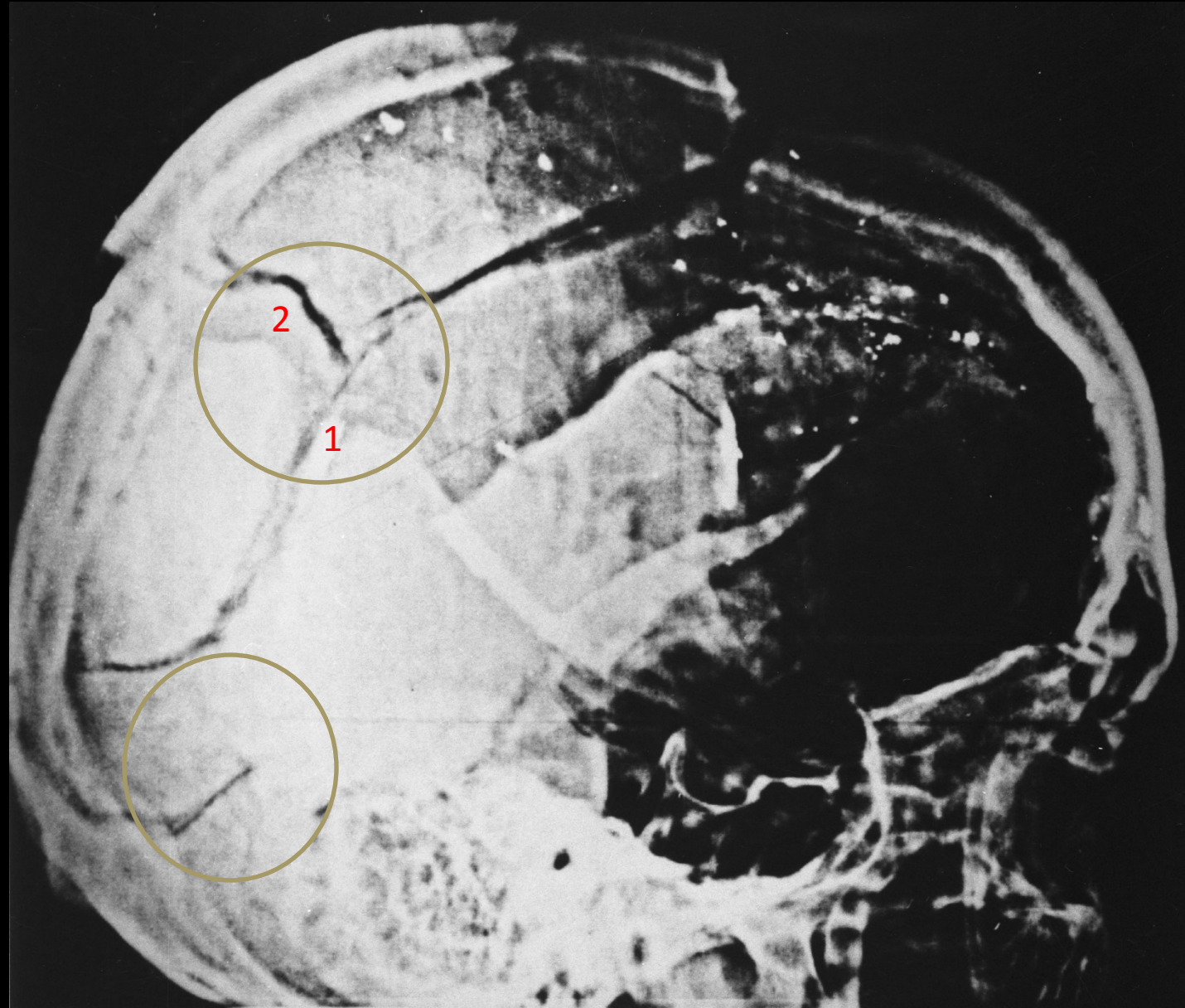Puppe's Rule



Fracture 1 occurred first; Fracture 2 stops when it encounters Fracture 1 (a fracture cannot propagate over empty space)

The right lateral x-ray shows fractures intersecting in the parietal area.

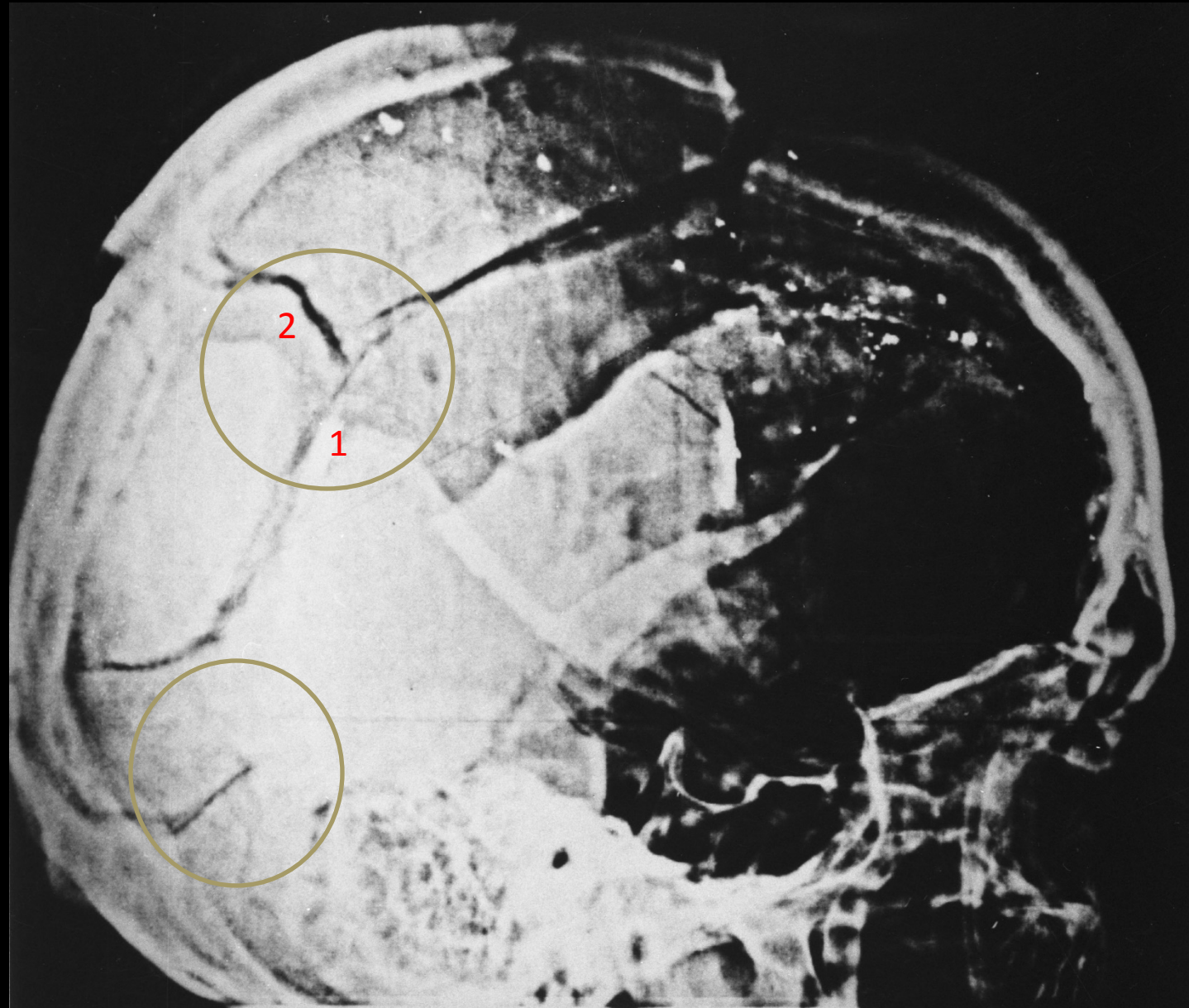Fracture 2 is consistent with a radial fracture, however it could not be a radial fracture from a single shot entering at the HSCA entry site, because it stops when it encounters fracture 1; fracture 1 occurred before fracture 2.



In the lower occipital- temporal area (lower circle) a fracture terminates when it runs into the “white patch”, an area of the skull which appears impossibly dense compared to the same region on the skull x-ray taken in 1960. I agree with David Mantik that this could have been altered by double exposure, to obscure bone loss, fractures, or fragments.

Fracture 2 stops at
Fracture 1,
therefore
Fracture 1 occurred
first

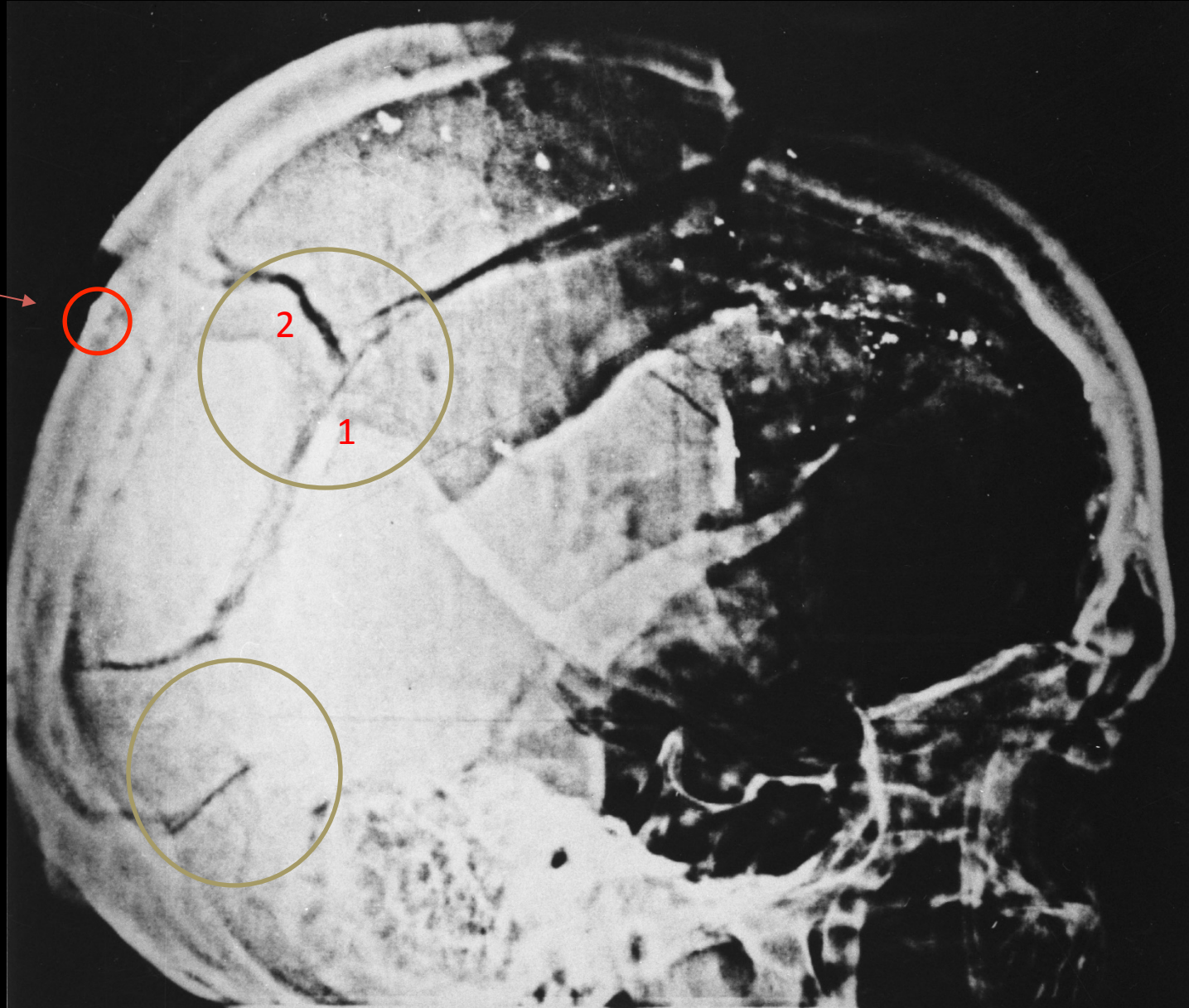This alone disproves the
HSCA and Clark panel's
conclusion that a single
shot entered the skull
at this location



Puppe's Rule

Fragment embedded in scalp

This fragment is embedded in the scalp, adjacent to the HSCA entry site. If the HSCA was correct, this fragment would necessarily have had to reverse course when the bullet impacted the skull.



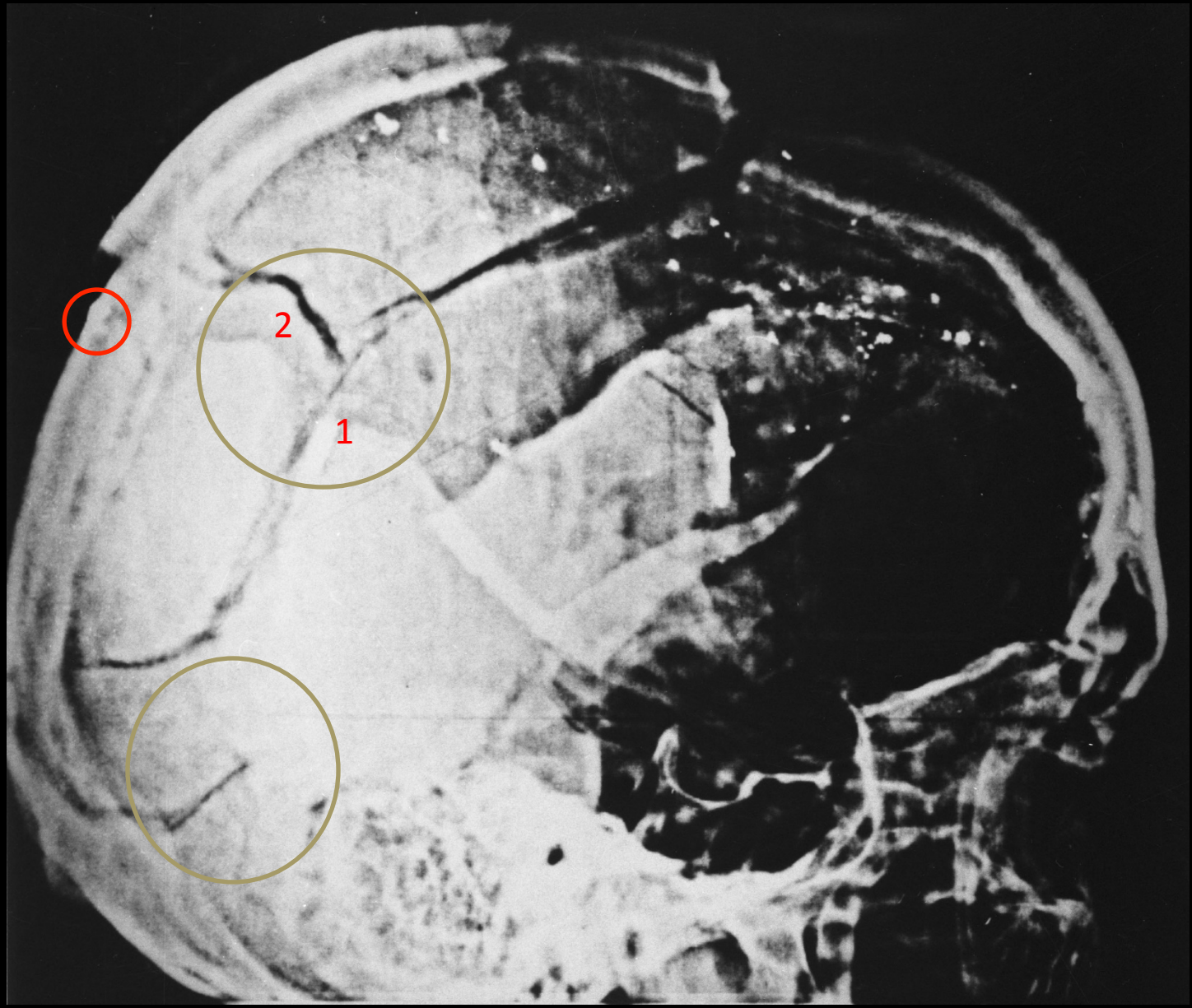Puppe's Rule

Arguments against HSCA entry site:

Fragment trail expands from front to back, in favor of this trail resulting from a frontal entry.

Fragment embedded in scalp

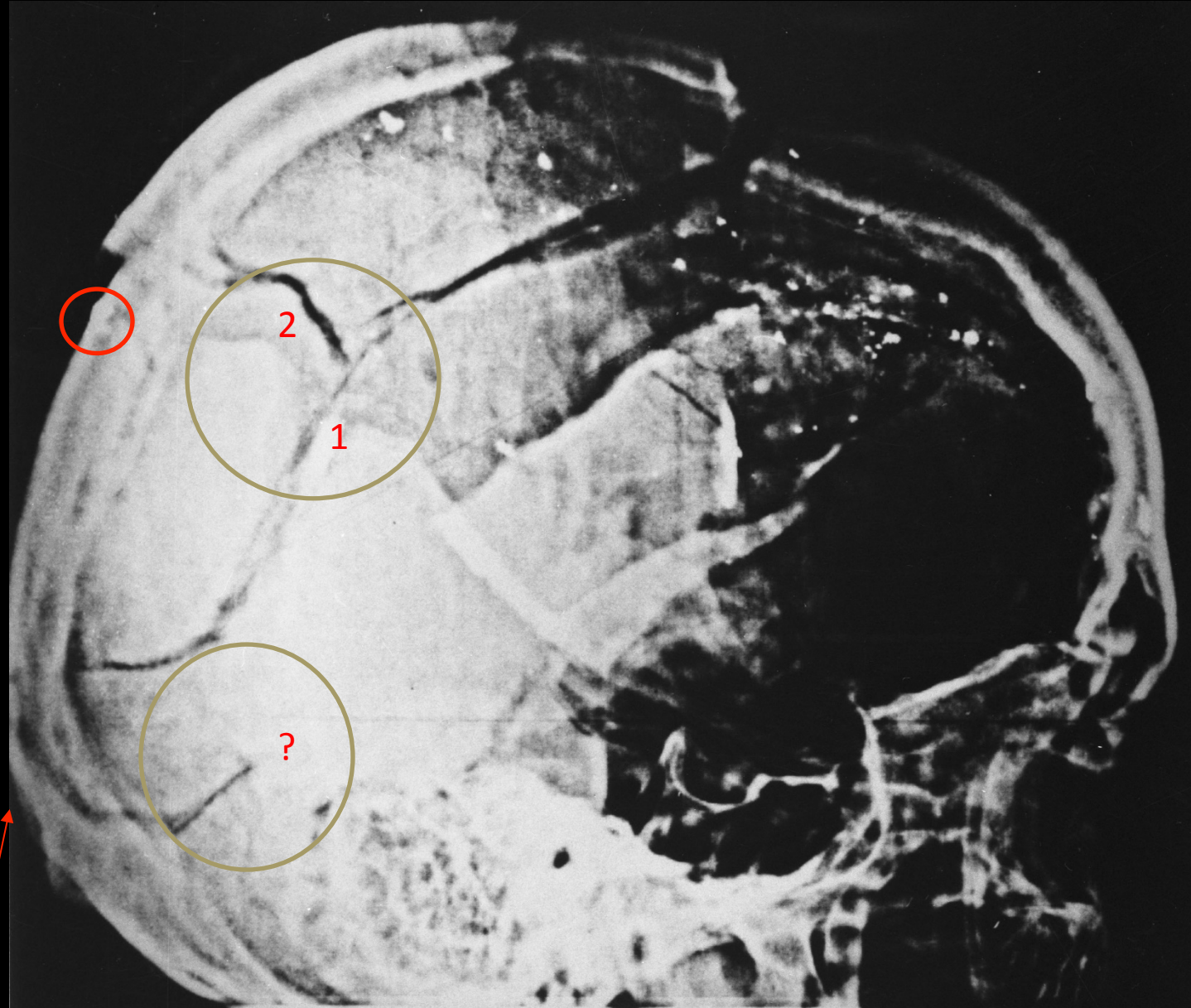
Puppe's rule shows that the fracture (2) associated with this site ends when it encounters Fracture 1.



Puppe's Rule

If the Warren Commission was correct, that a single shot impacted the skull in the right lower occiput, how can we explain the:

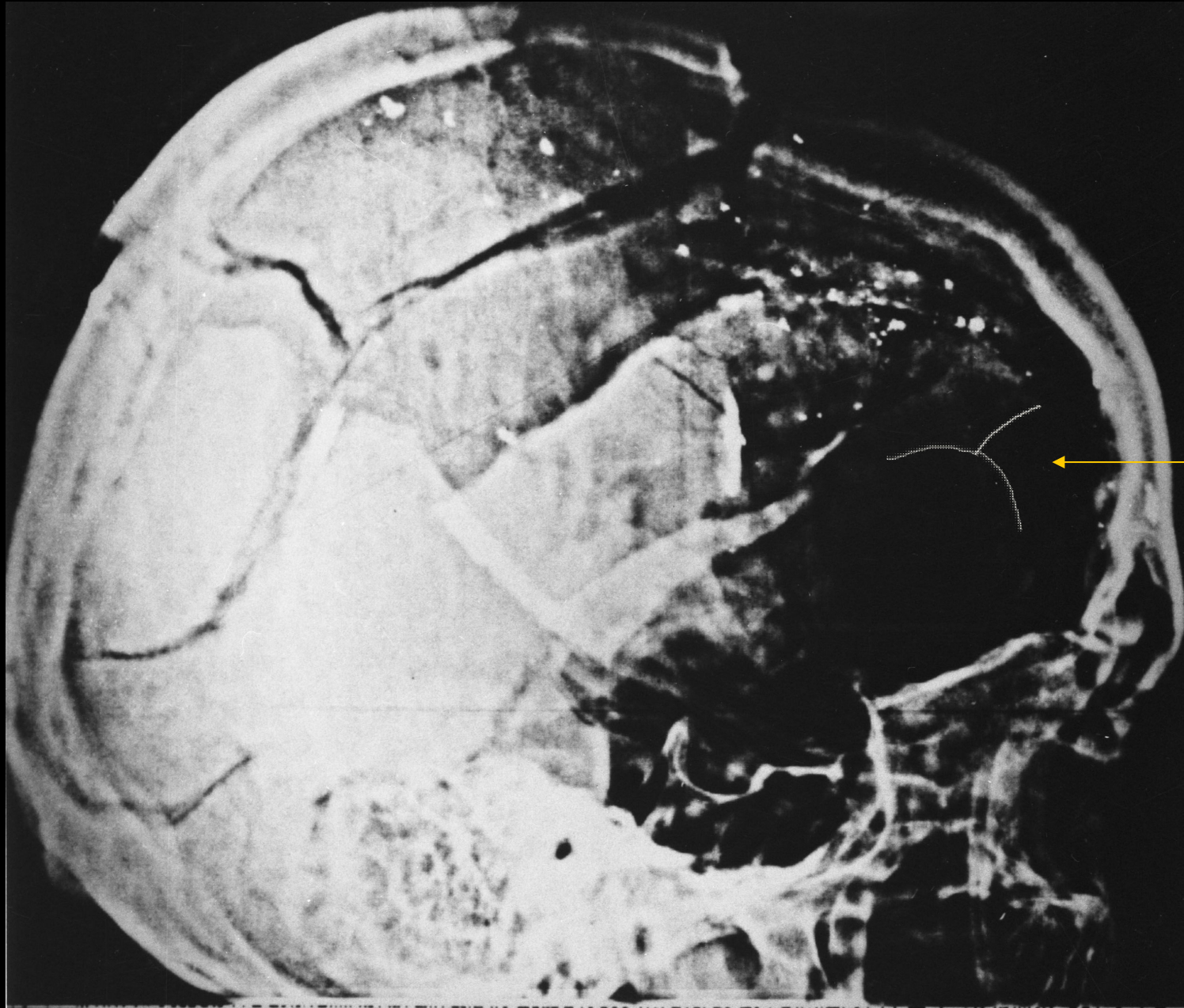
- Fragment trail ?
- Fragment located between scalp and skull near the HSCA location ?
- Trajectory from TSBD ? (to be discussed)



TSBD = Texas School Book Depository 6th floor

Warren Commission entry

Puppe's Rule



Simulation of location and shape of fractures visible on the HSCA lateral x-rays at the Archives

This escaped my attention the first time I viewed the HSCA films. It is not visible on the HSCA report image. It could be a radial fracture from the frontal entry, which then branched, or terminated when it encountered a pre-existent concentric fracture.

The Photographs of the Brain

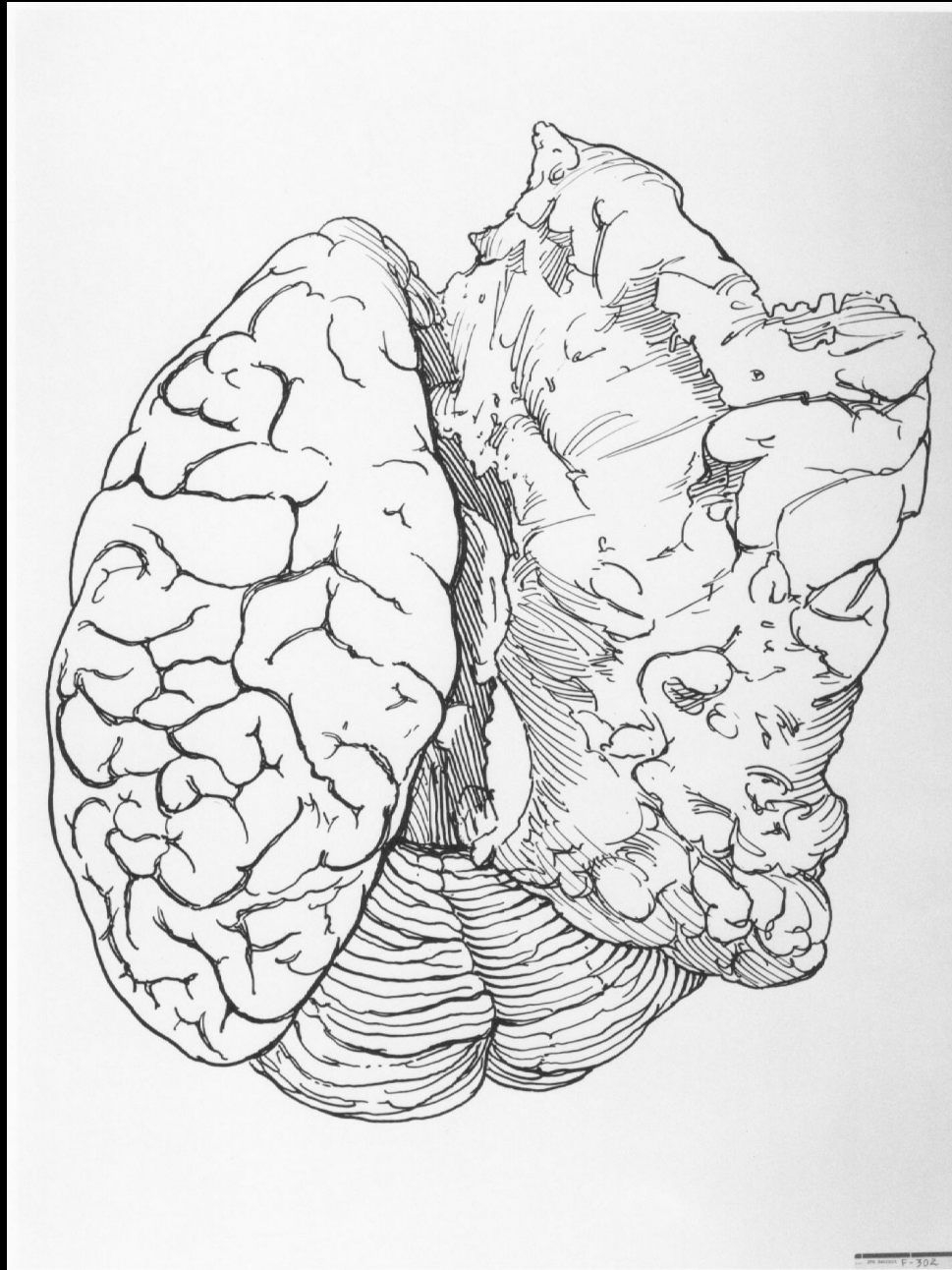
HSCA Medical Panel Testimony: Dr. Petty of
the Medical Panel, questions
Dr. Humes, chief autopsy pathologist (1978)

Dr. Petty: “Well, we have some interesting information in the form of the **photographs of the brain**, and if this wound were way low, we would wonder at the **occipital** lobes, such as are shown in Figure 21. Here the **cerebellum** is intact, as well as the **occipital** lobes, and this has concerned us right down the line as to where precisely the inshoot wound was, and this is why we found ourselves in a quandary, and one of the reasons that we very much wanted to have you come down today”.

HSCA JFK Exhibit F-302

Illustration of the brain photograph (dorsal view) which was placed in the HSCA report

The actual brain photograph showed that there was subarachnoid blood over the surface of the left hemisphere, and the brain appeared somewhat small and somewhat deformed, like a brain sitting in a jar for a prolonged period.



The dorsal view showed no loss of tissue of the left hemisphere or of the cerebellum

Trajectory Hypothesis of the House Select Committee from TSBD 6th floor

36

LOCATION OF HEAD WOUNDS IN PRESIDENT KENNEDY

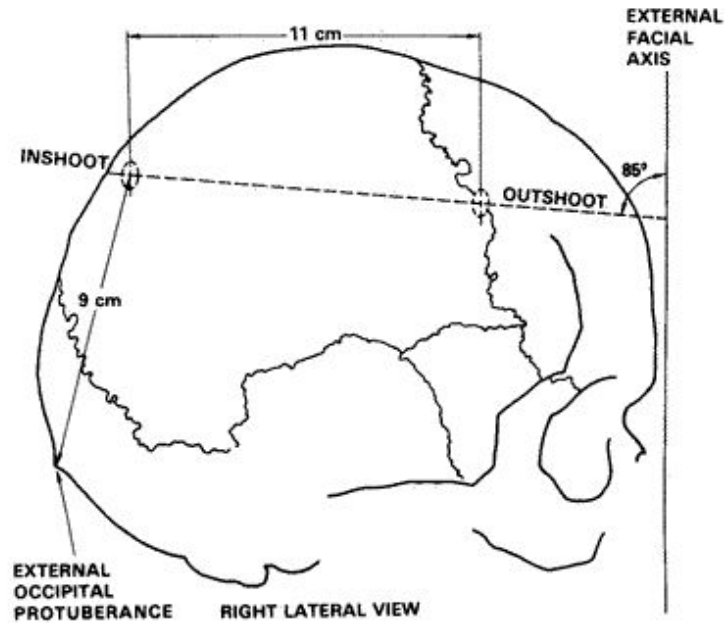
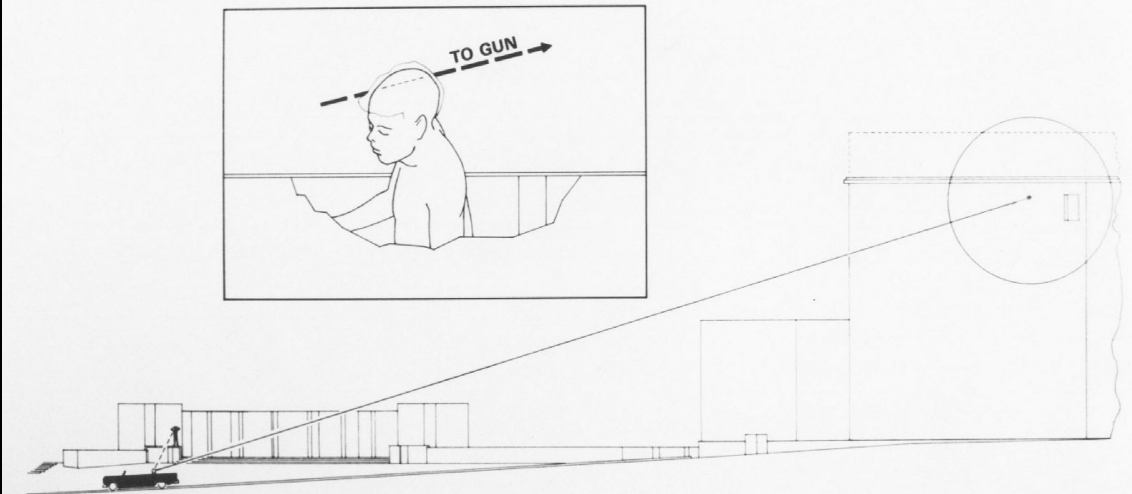


FIGURE II-6

LINE OF SIGHT FROM ZAPRUDER CAMERA TO JFK/SLOPE OF BULLET CAUSING HEAD WOUND



These illustrations are included in the HSCA report, showing the trajectory analysis. The autopsy pathologists did not identify any entry or exit wound at either the inshoot or outshoot locations, in the autopsy report.

Trajectory from TSBD 6th floor carried forward through Warren Commission entry site (in RED)

36

LOCATION OF HEAD WOUNDS IN PRESIDENT KENNEDY

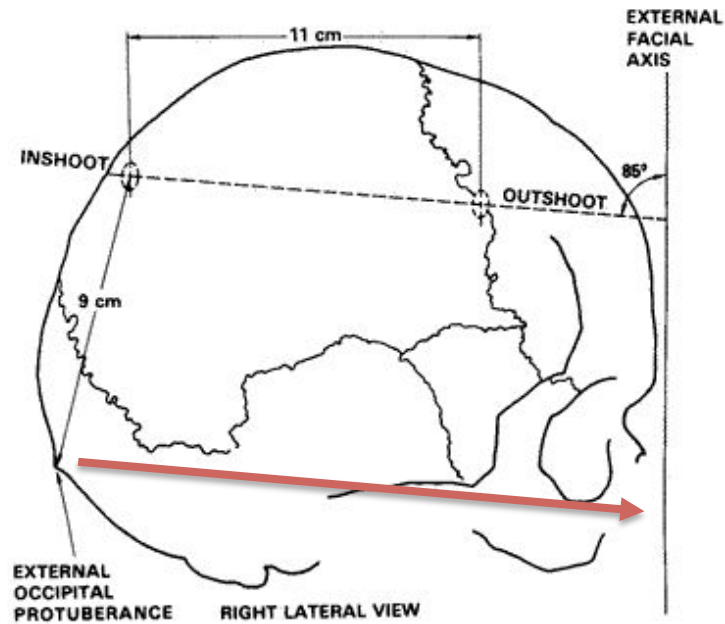
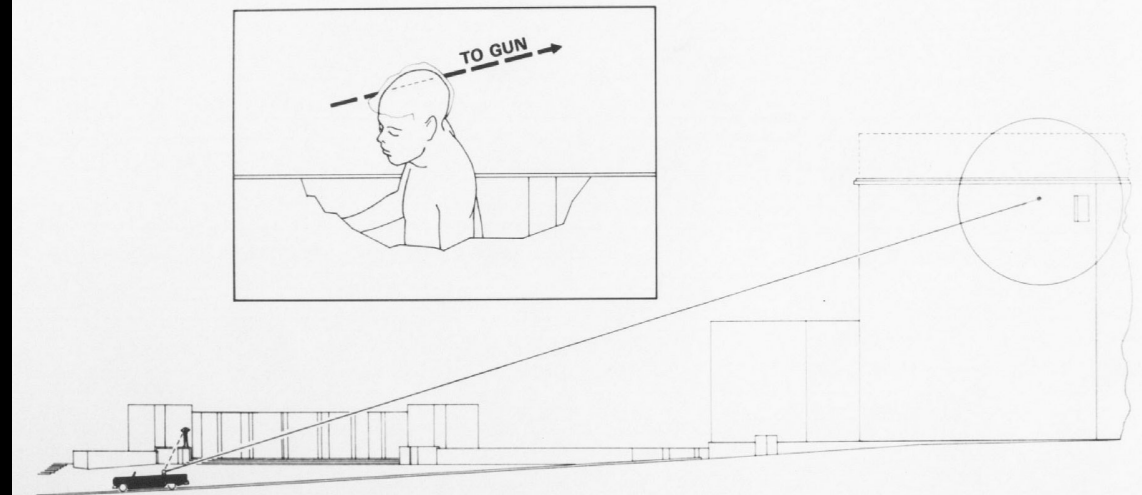


FIGURE II-6

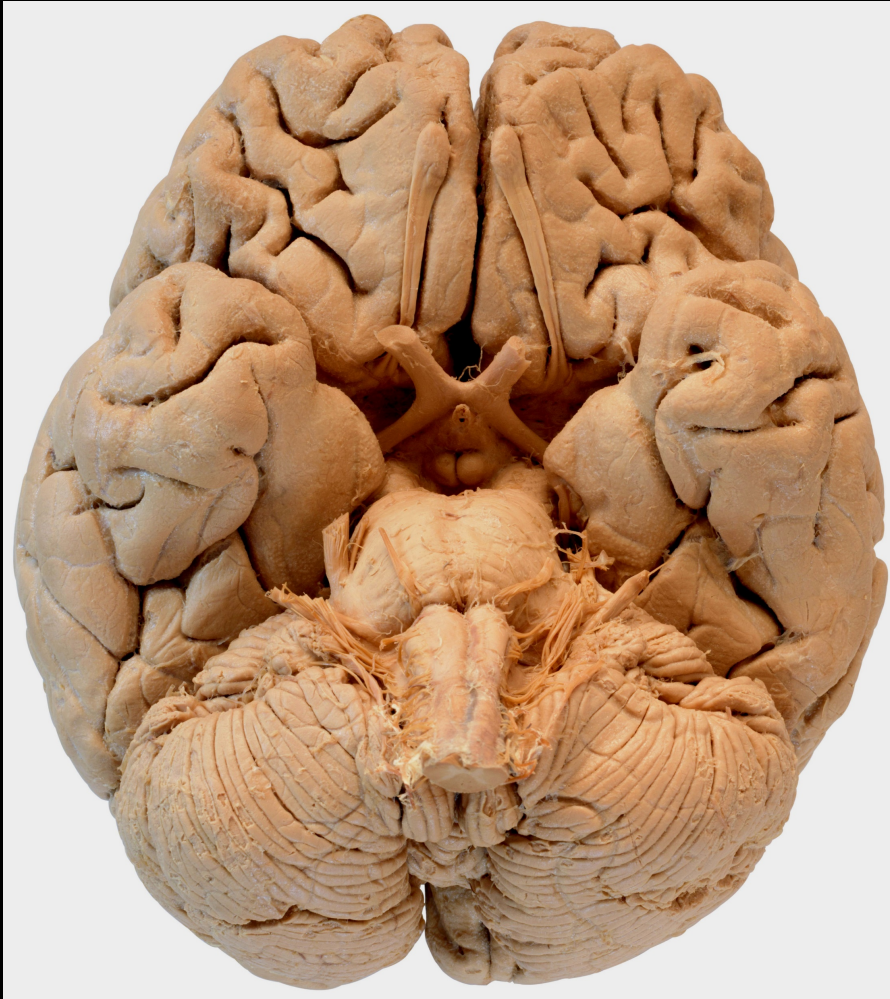LINE OF SIGHT FROM ZAPRUDER CAMERA TO JFK/SLOPE OF BULLET CAUSING HEAD WOUND



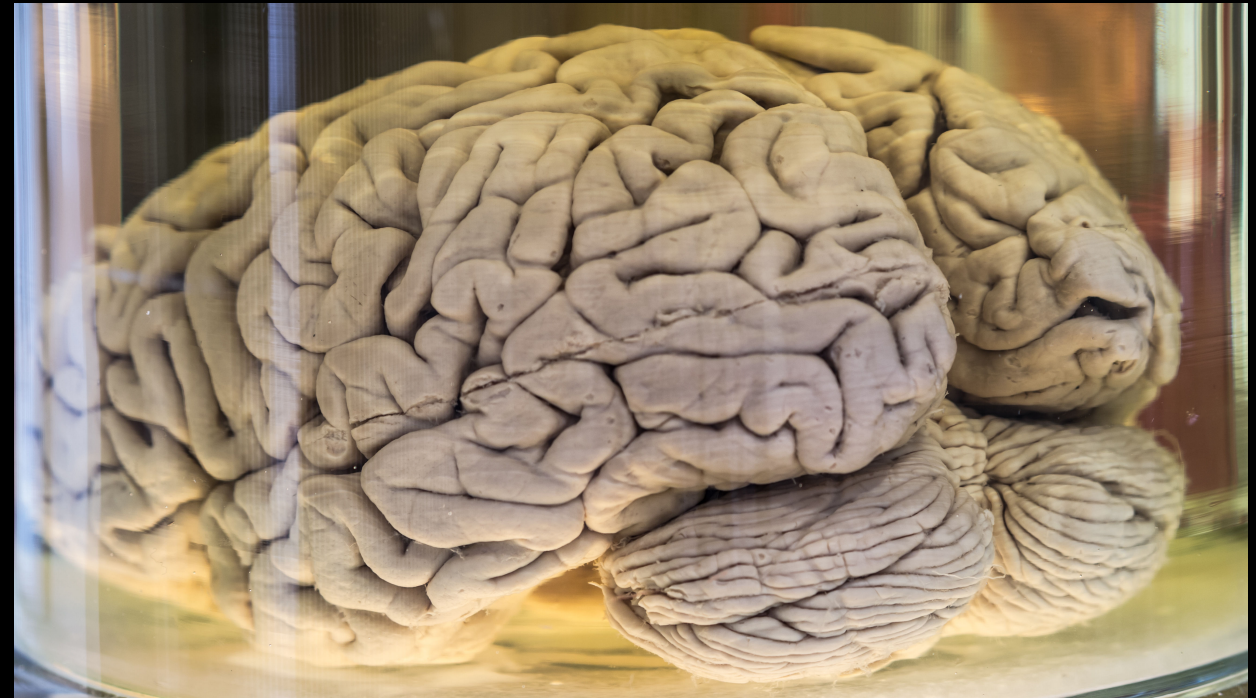These trajectory illustrations are shown to demonstrate that the trajectory from the TSBD 6th floor window through the skull would have exited below the level of the eyes.

This location for an entry wound is much more compatible with a shot fired from a lower floor of the DalTex building, than a shot fired from the TSBD 6th floor

These examples of preserved brains are shown to demonstrate the appearance of the inferior surface of the brain, and also a saw mark on the surface of the brain, made when the saw used to remove the skull cap barely cuts the brain.



Example of inferior surface of brain



Example of saw mark

The inferior brain photograph at the Archives showed that the cerebellum was intact, except for a tiny folia hanging loose on the left side. There was also a saw mark extending the length of the left side of the brain.



Example of inferior surface of brain

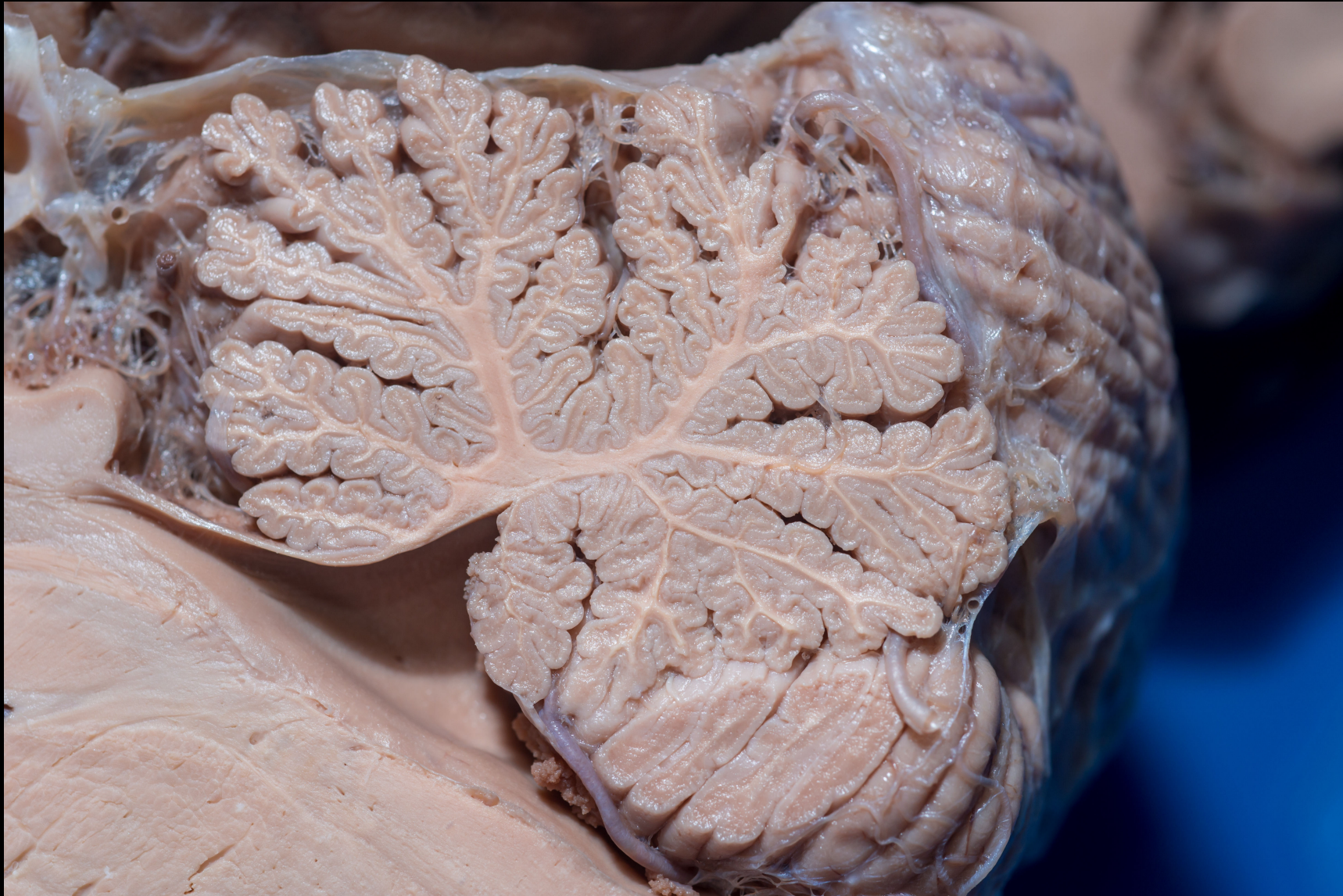

Example of saw mark

Cerebellum

This example of preserved cerebellum shows the remarkable delicate features of the **cerebellum**.

The branching structures are 'folia', similar to the branches and leaves of a tree.

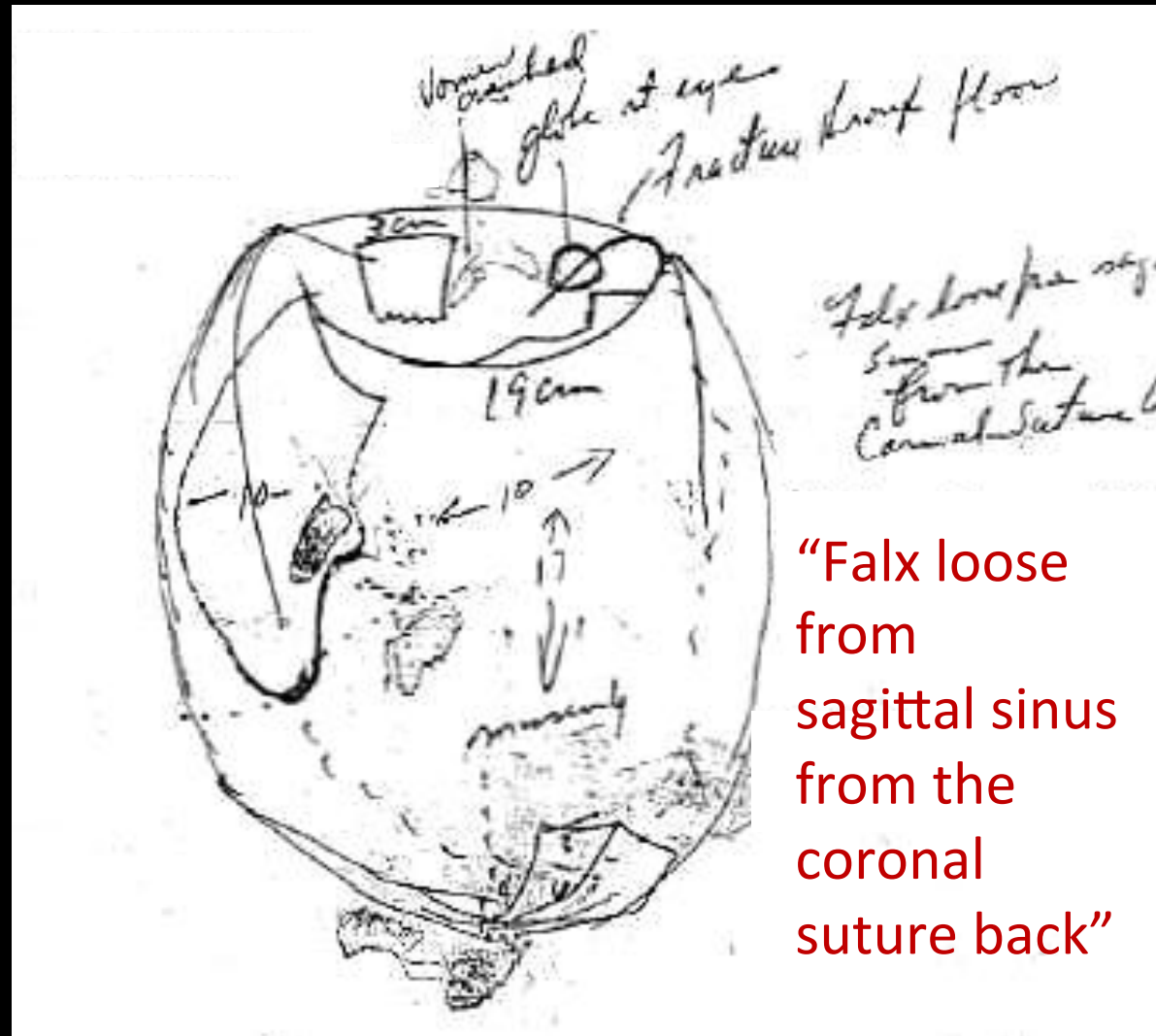


Kemp Clark, M.D.
Univ. of Texas Southwestern
Chairman of Neurosurgery

Handwritten statement of 11-22-63: “...there was a large wound in the right occipitotemporal region, from which profuse bleeding was occurring.....
Both cerebral and cerebellar tissue were extruding from the wound.”

Warren Commission testimony: “Just let me state that the **loss of cerebellar tissue** would probably have been of minimal consequence in the performance of his duties. The loss of the right occipital and probably part of the right parietal lobes would have been of specific importance.”

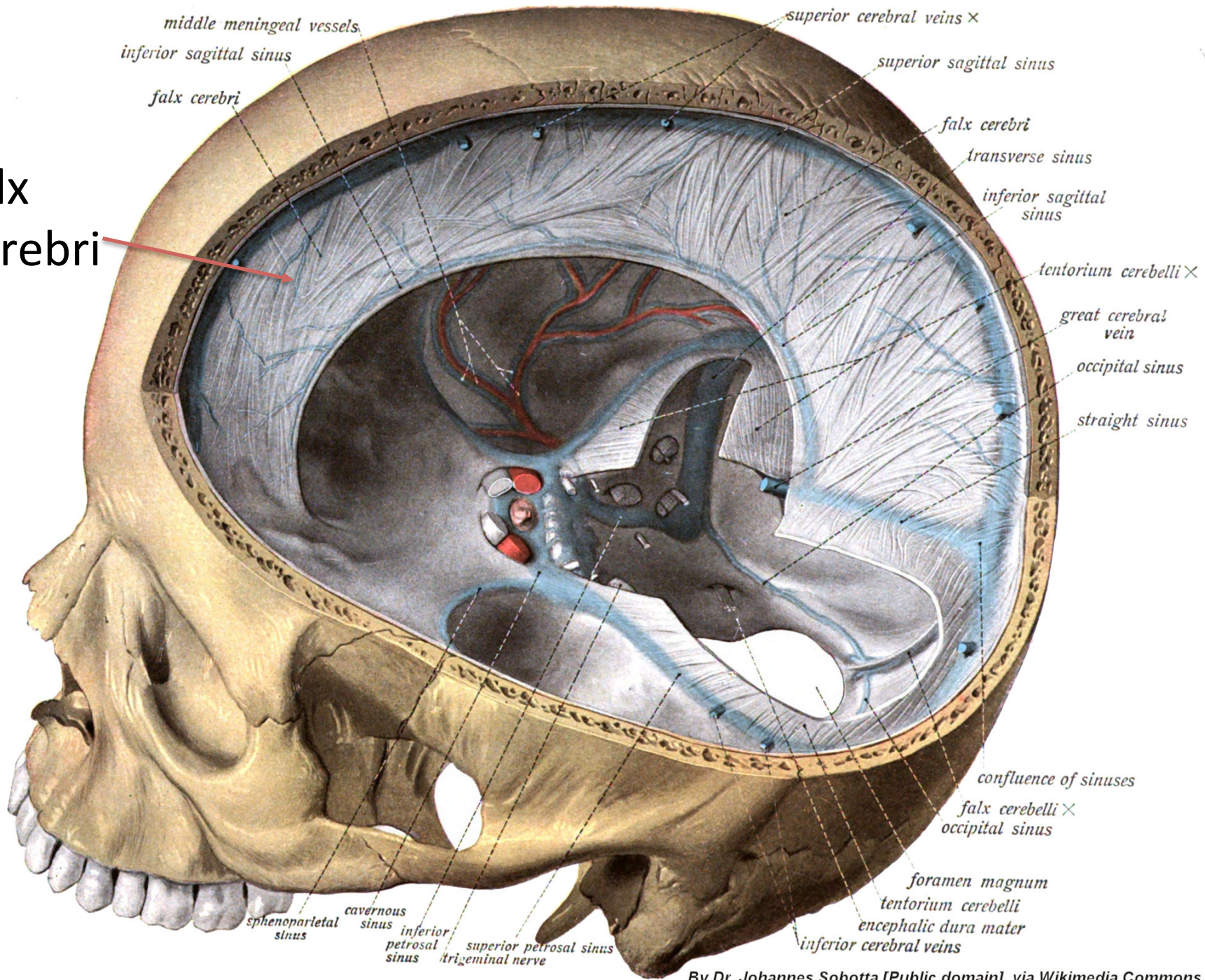
Commander J. Thornton Boswell's autopsy drawing



“Falx loose from sagittal sinus from the coronal suture back”

The falx is a very tough fibrous band which is like the head of a drum – very tight. It separates the upper half of the hemispheres of the brain. Not only was the falx torn over much of its length, but also there was loss of bone extending across the midline

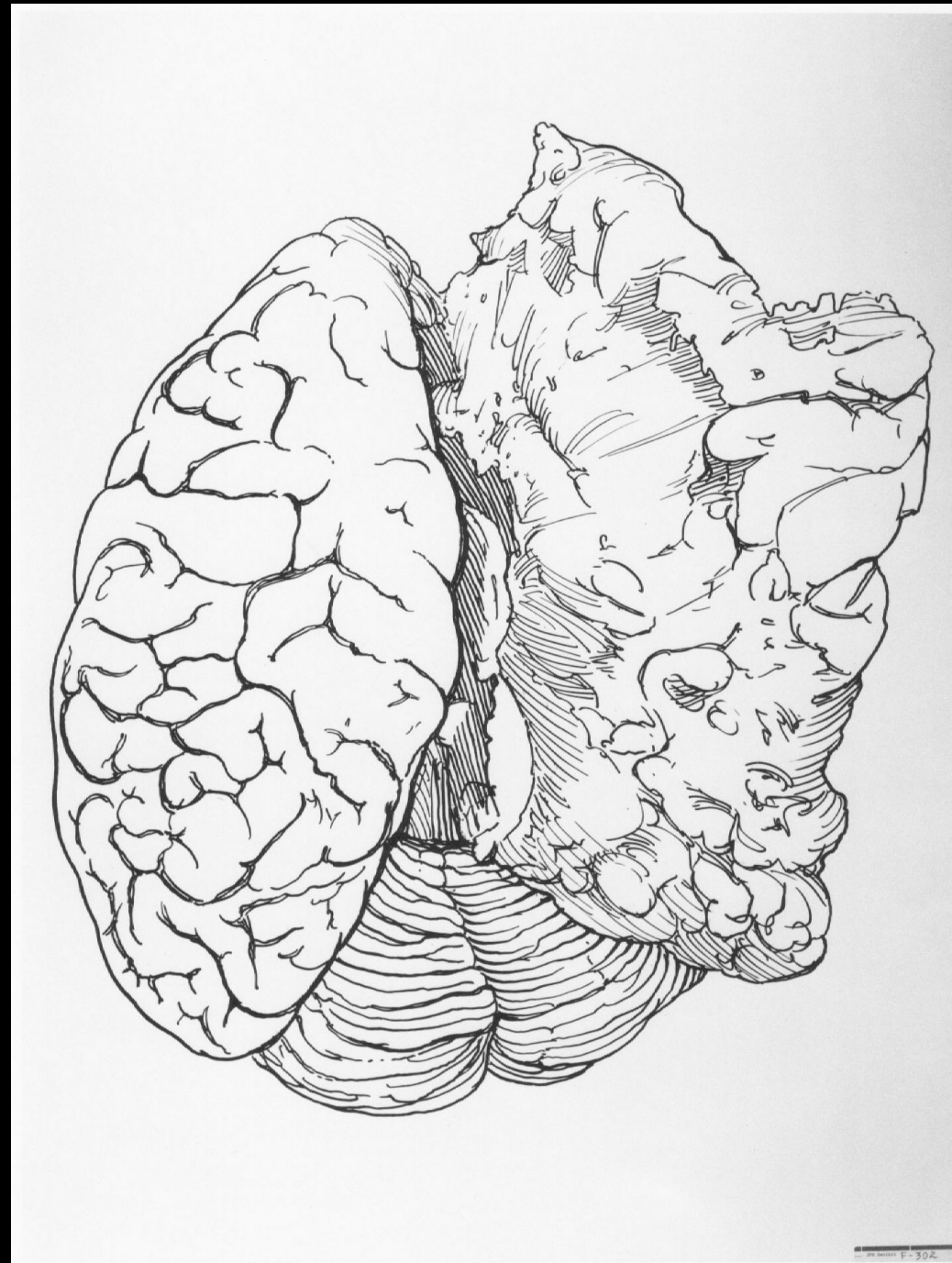
Falx Cerebri



“Falx loose from sagittal sinus from the coronal suture back”

How can the falx be torn, and the overlying skull be damaged, with loss of bone over the left side, yet the adjacent delicate brain tissue showed no loss of tissue?

This defies the imagination.



The Brain Photographs at the Archives are not of President Kennedy's Brain

- The brain appeared small and deformed, and it appeared most like a brain which had been sitting in a jar for a long period of time (these photographs were purported to be taken at the supplemental brain exam a few days after the autopsy)
- The **cerebellum** showed no damage except for a small folia hanging loose on the left side and no damage whatsoever on the right side
- Multiple **Parkland ER** physicians and nurses and multiple personnel at **Bethesda** placed the large head wound in the right occipital area
- **Dr. Kemp Clark** (as well as multiple other physicians and nurses) knew the difference between cerebrum and cerebellum

The brain photographs at the Archives are not of President Kennedy's brain

- **John Stringer**, Navy autopsy photographer, testified under oath to the Assassinations Records Review Board that he did not believe the brain photographs from the supplementary brain examination could be the photographs he took
- The loss of skull extended across the midline into the left parietal region, and the falx was extensively torn, yet the brain photograph shows **no damage whatsoever to the left hemisphere** – it is inconceivable that these tough structures were damaged without the adjacent brain tissue suffering damage
- The ventral brain photograph shows a faint saw mark extending along the left side – those in attendance at the autopsy either stated that Dr. Humes did not use a saw or required minimal use of the saw

Summary

- The **x-rays** do support a right frontal entry
- The **x-rays** do support a right lower occipital entry, but **not** one fired from the 6th floor of the Texas School Book Depository
- **False assumptions based upon the autopsy photographs** caused the Clark panel and the HSCA medical panel to try to “fit” the x-rays into the Oswald/TSBD hypothesis

Summary

- I can only speculate that the **military pathologists** were ordered to avoid any discussion which was not in line with the hypothesis of a single shooter on the TSBD 6th floor
- **The evidence was altered**
 - The brain photographs
 - The x-rays
 - The autopsy photographs of the back of the head